Reunión Territorial SEAP Madrid

30/05/2008

Ley de Murphy de la Termodinámica:

“Todo empeora a altas presiones”

- Niña de 13 años de edad
- Tumor en región deltoidea
- 2 meses de evolución

Lesión nodular

Hipodermis

2 cms diámetro

Contenido heterogéneo

Incremento de densidad periférica adyacente

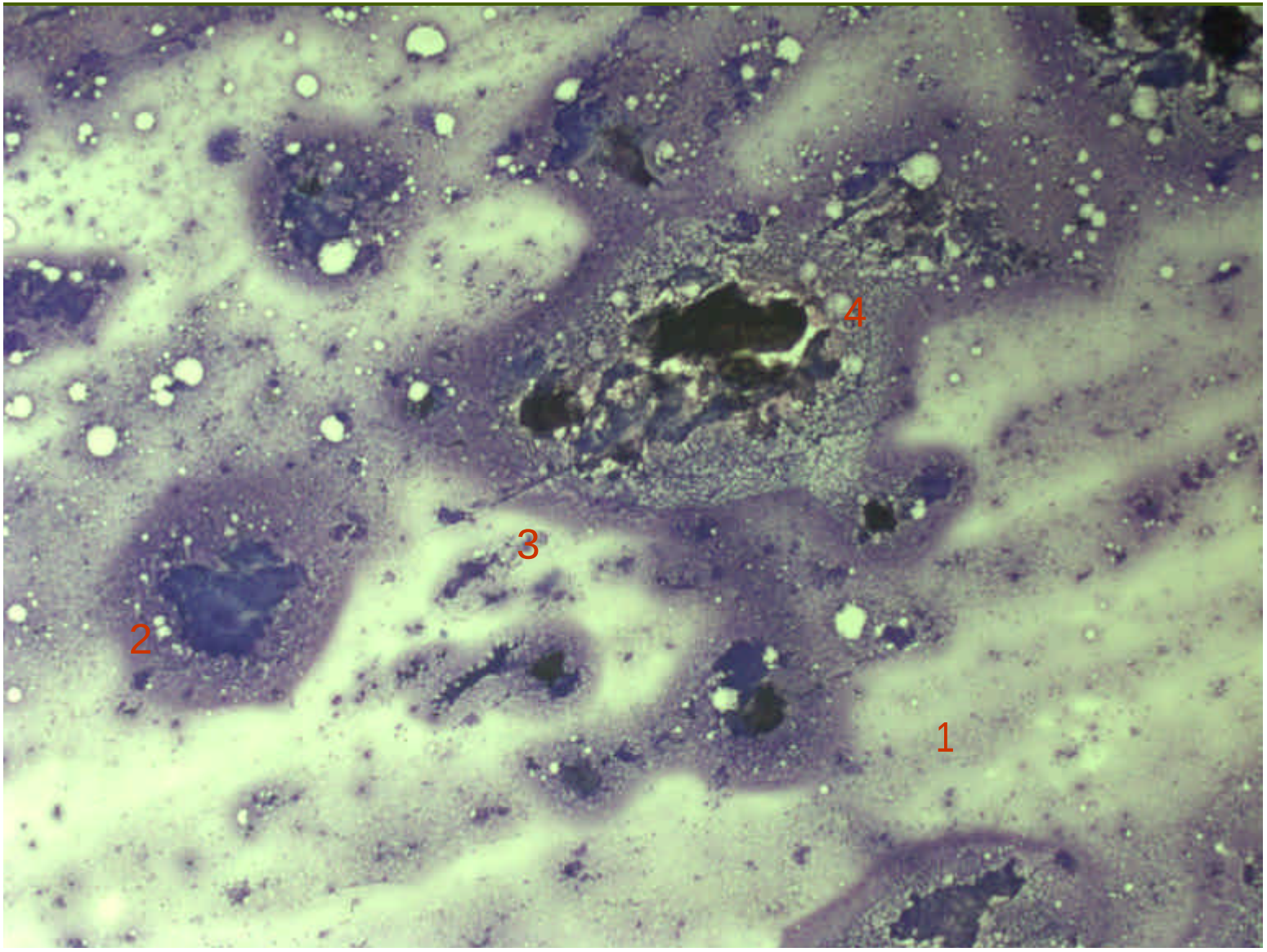
4
3
2
1

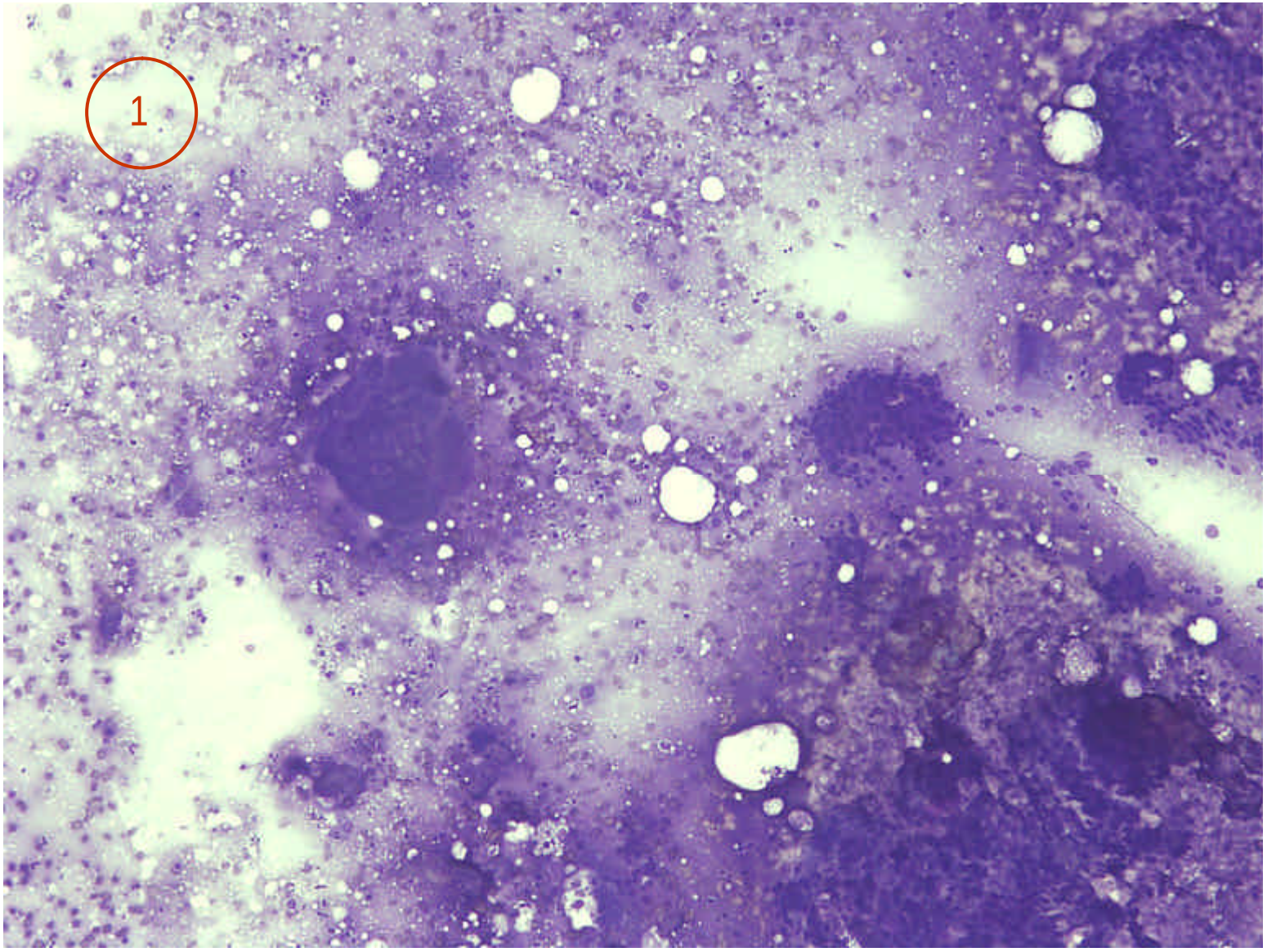
1

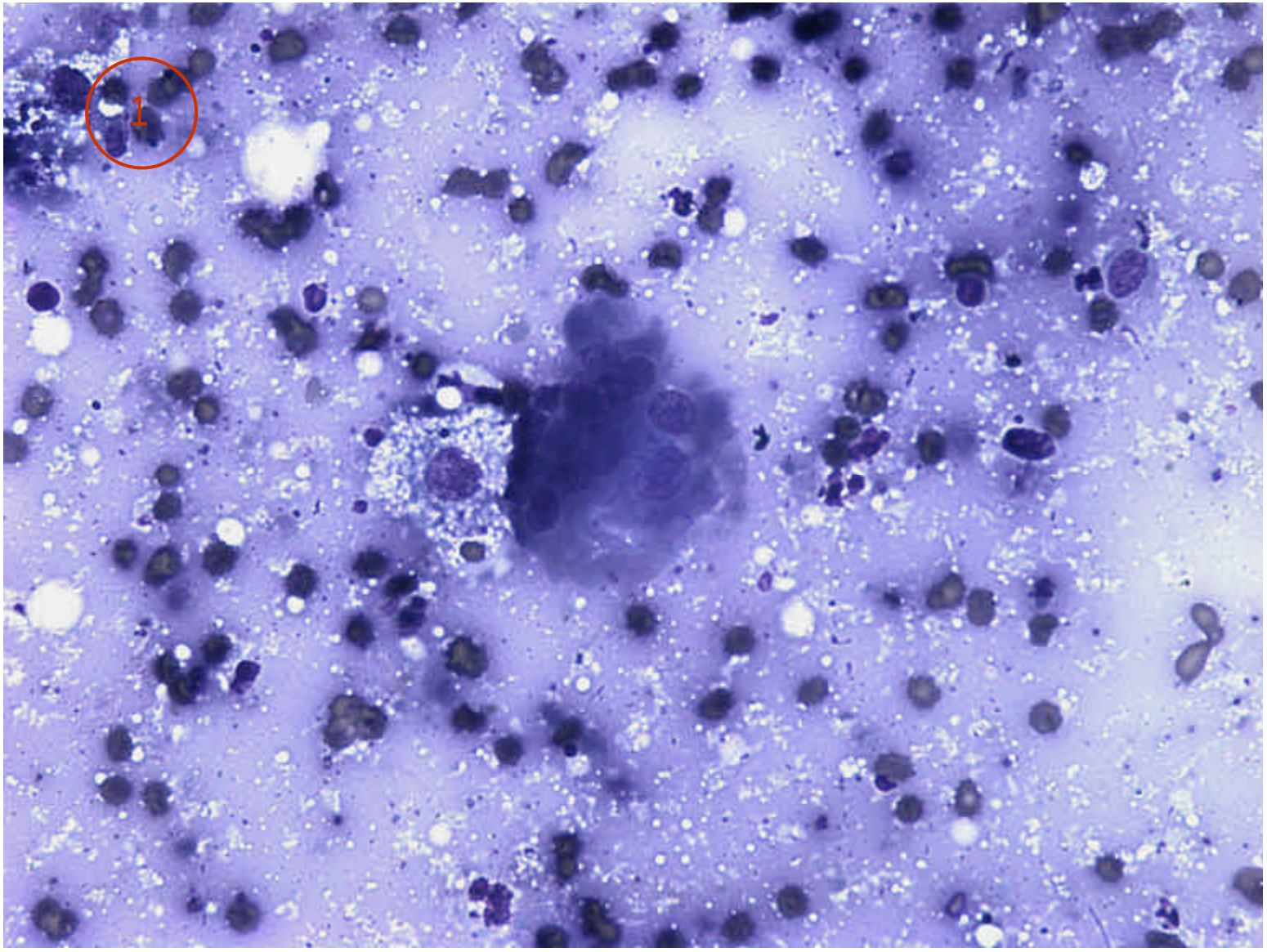
1

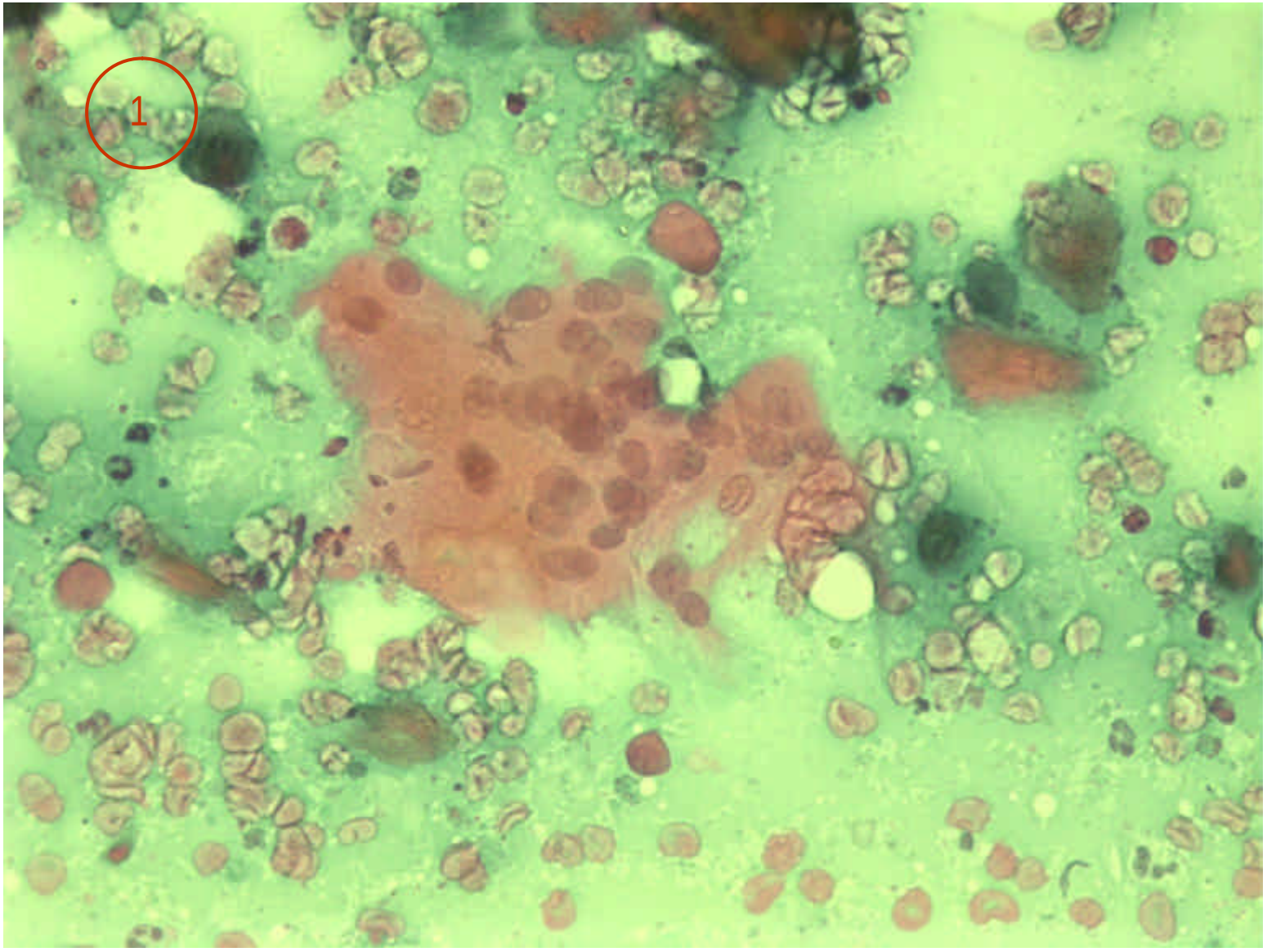
1

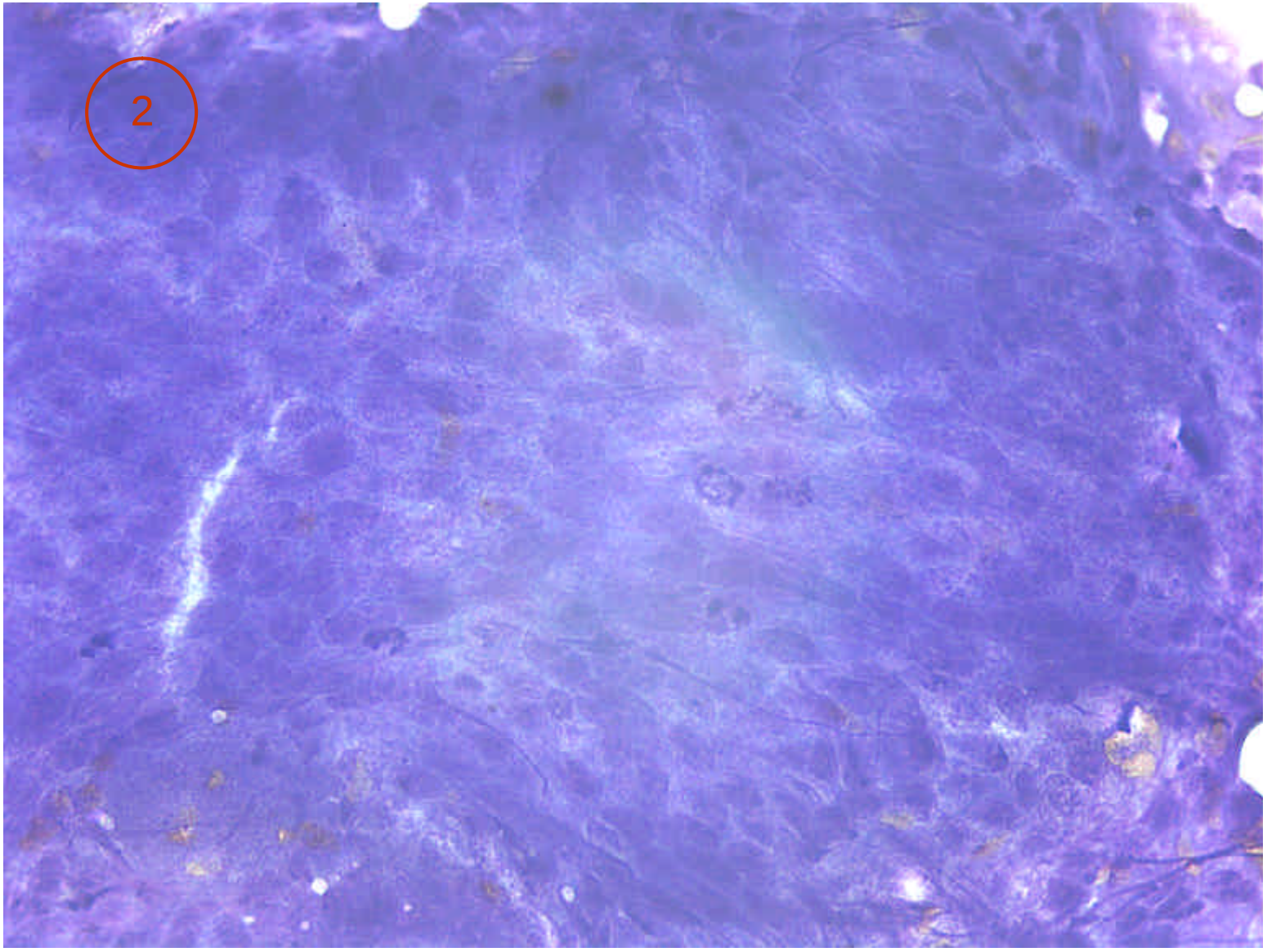
2

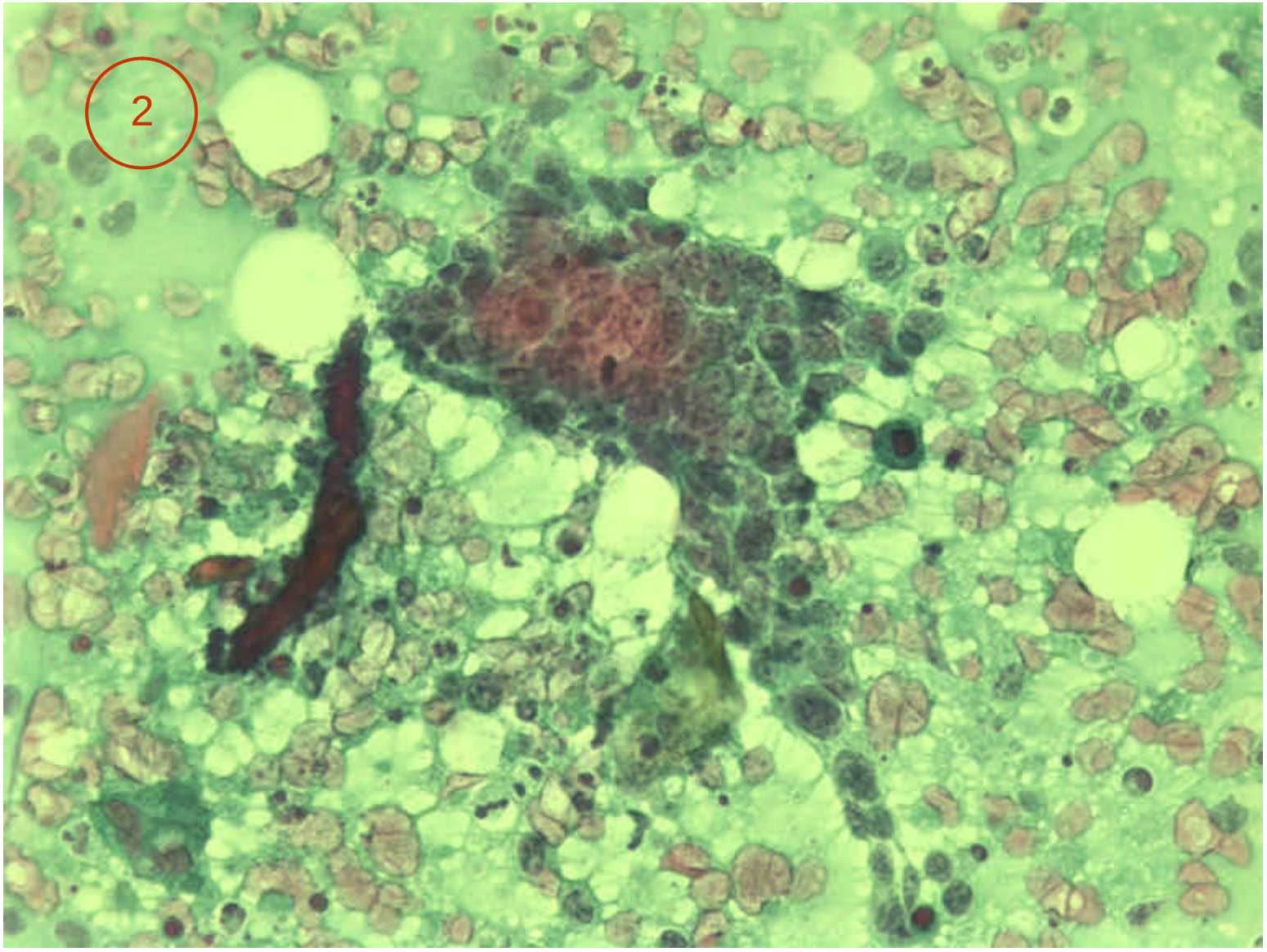
2

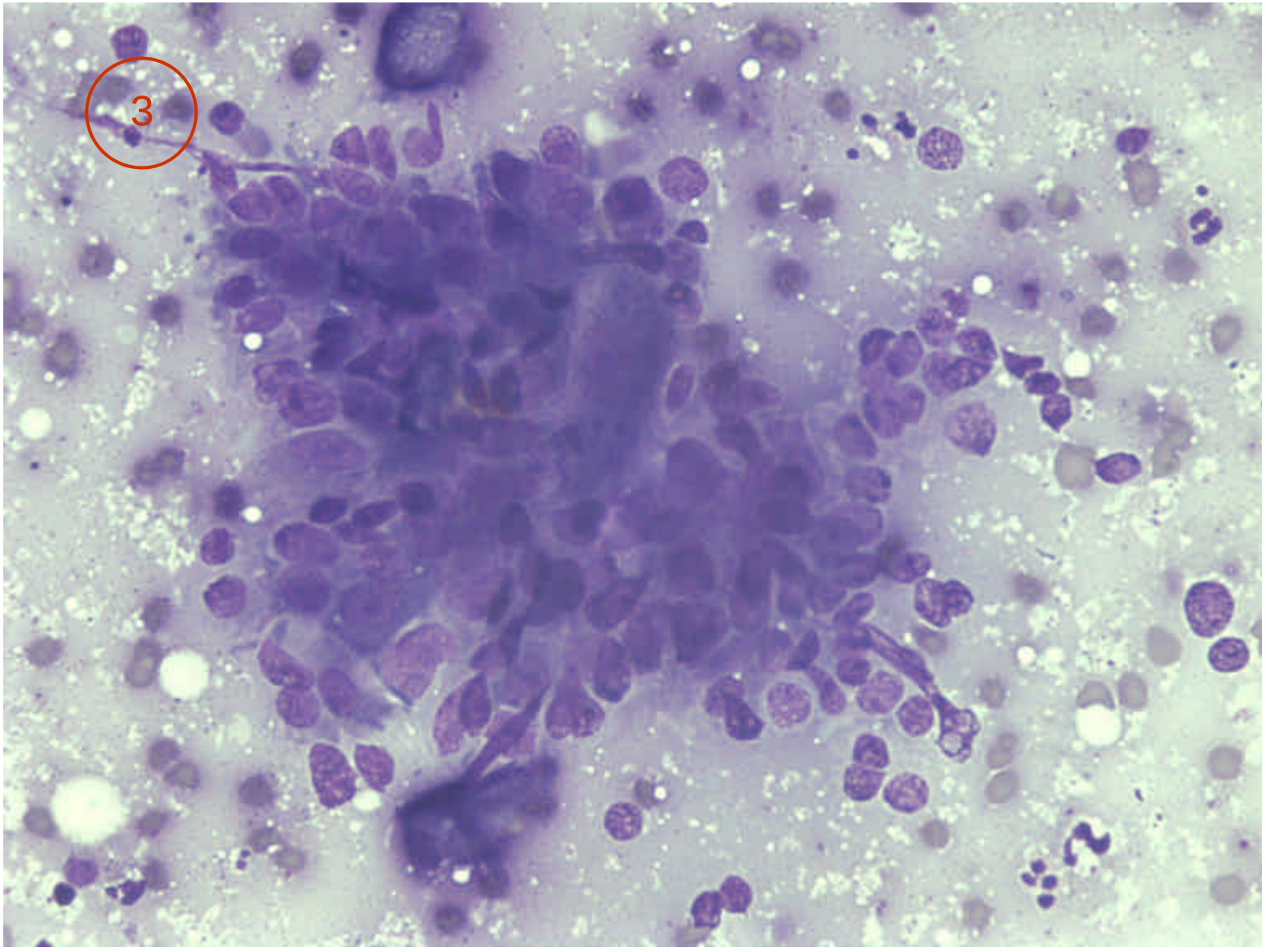
3

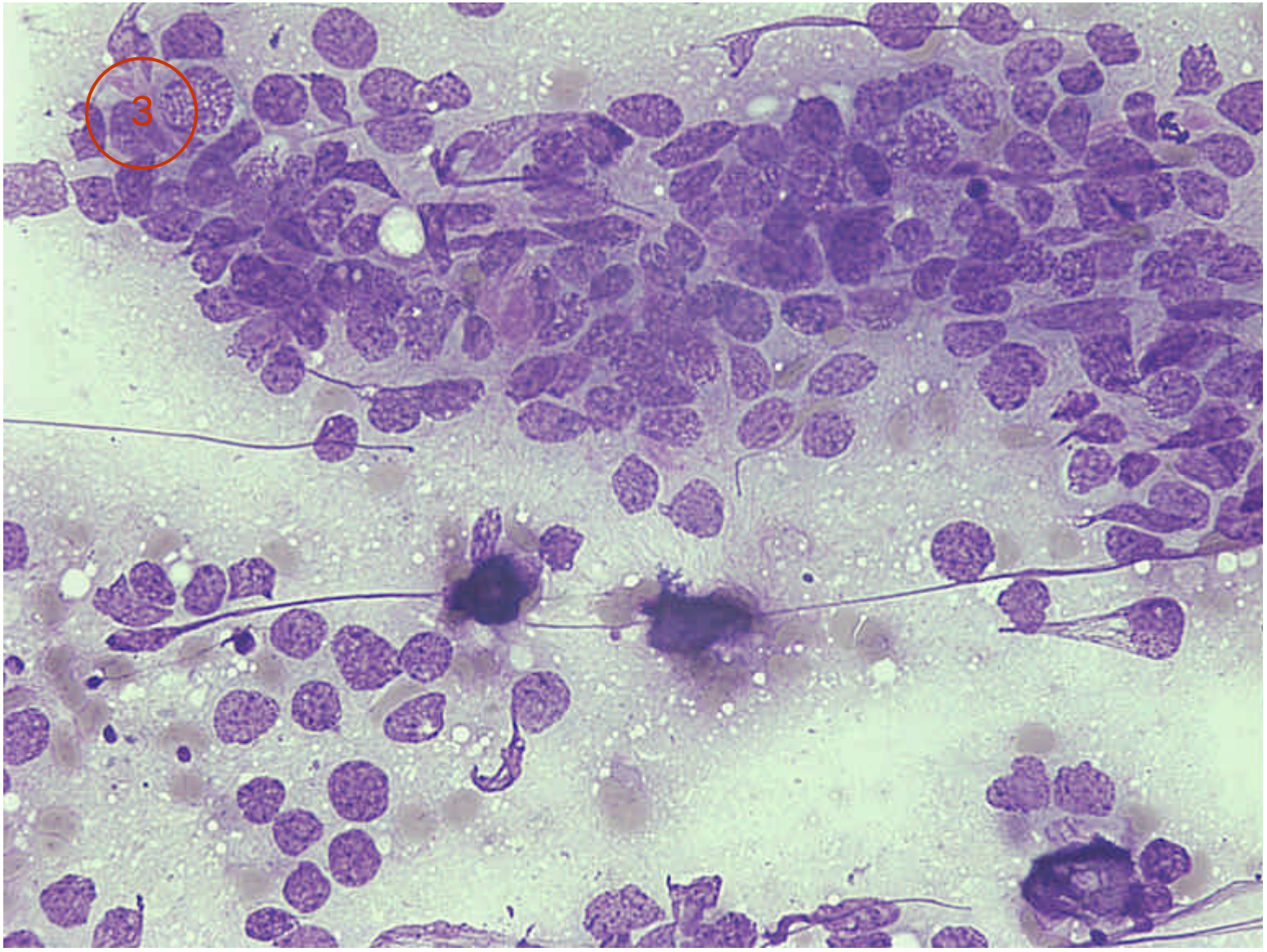
3

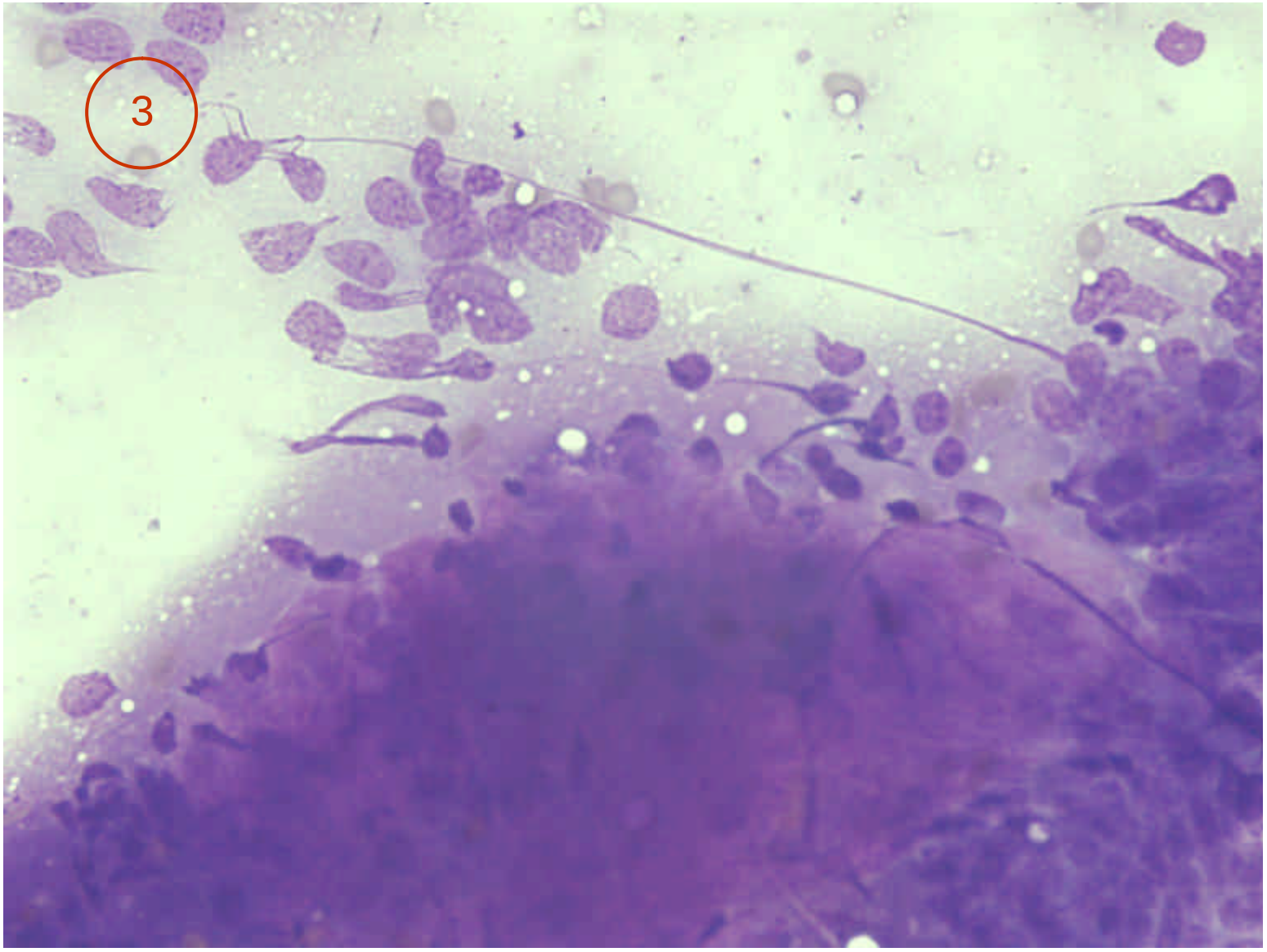
3

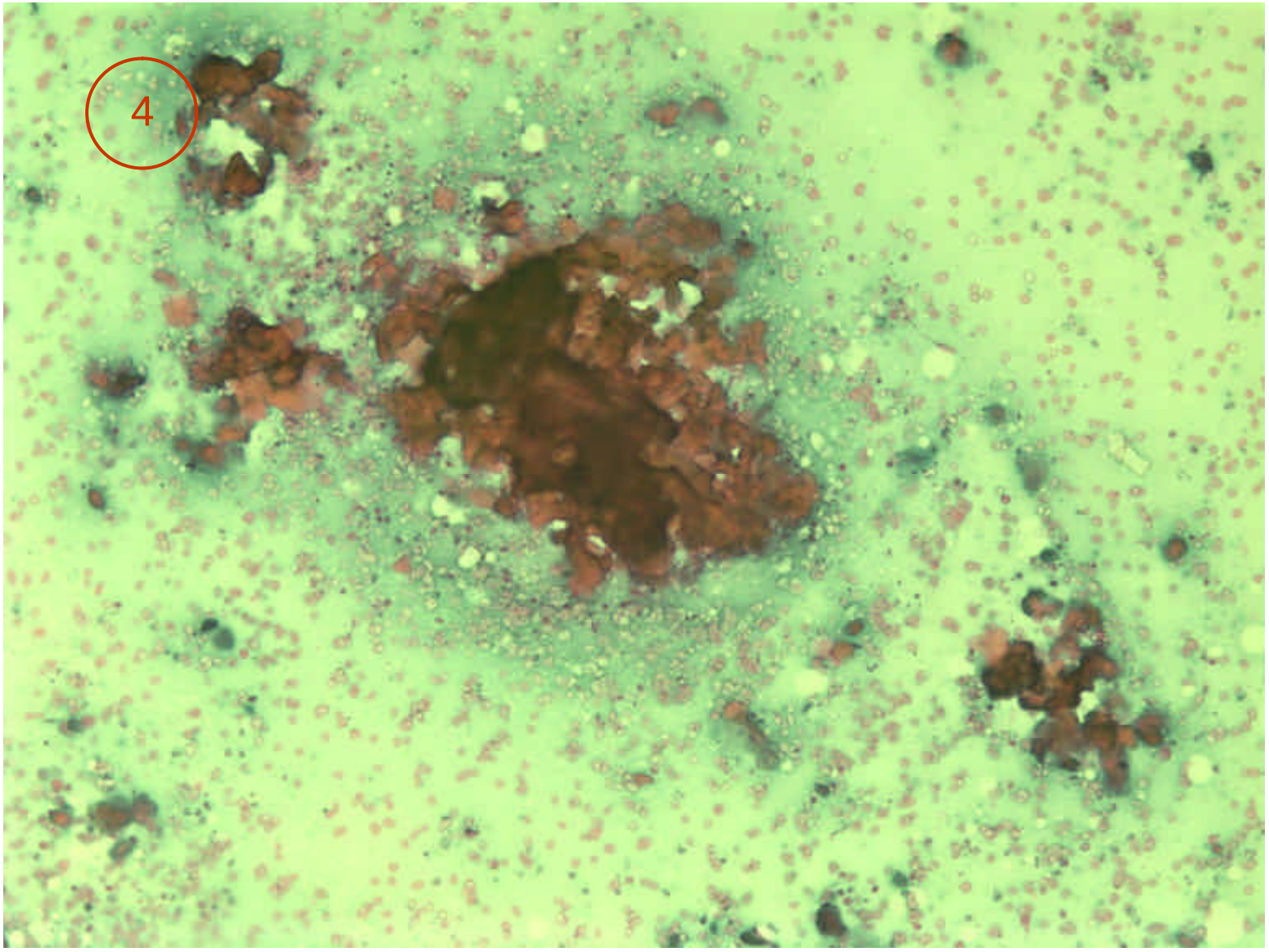
4

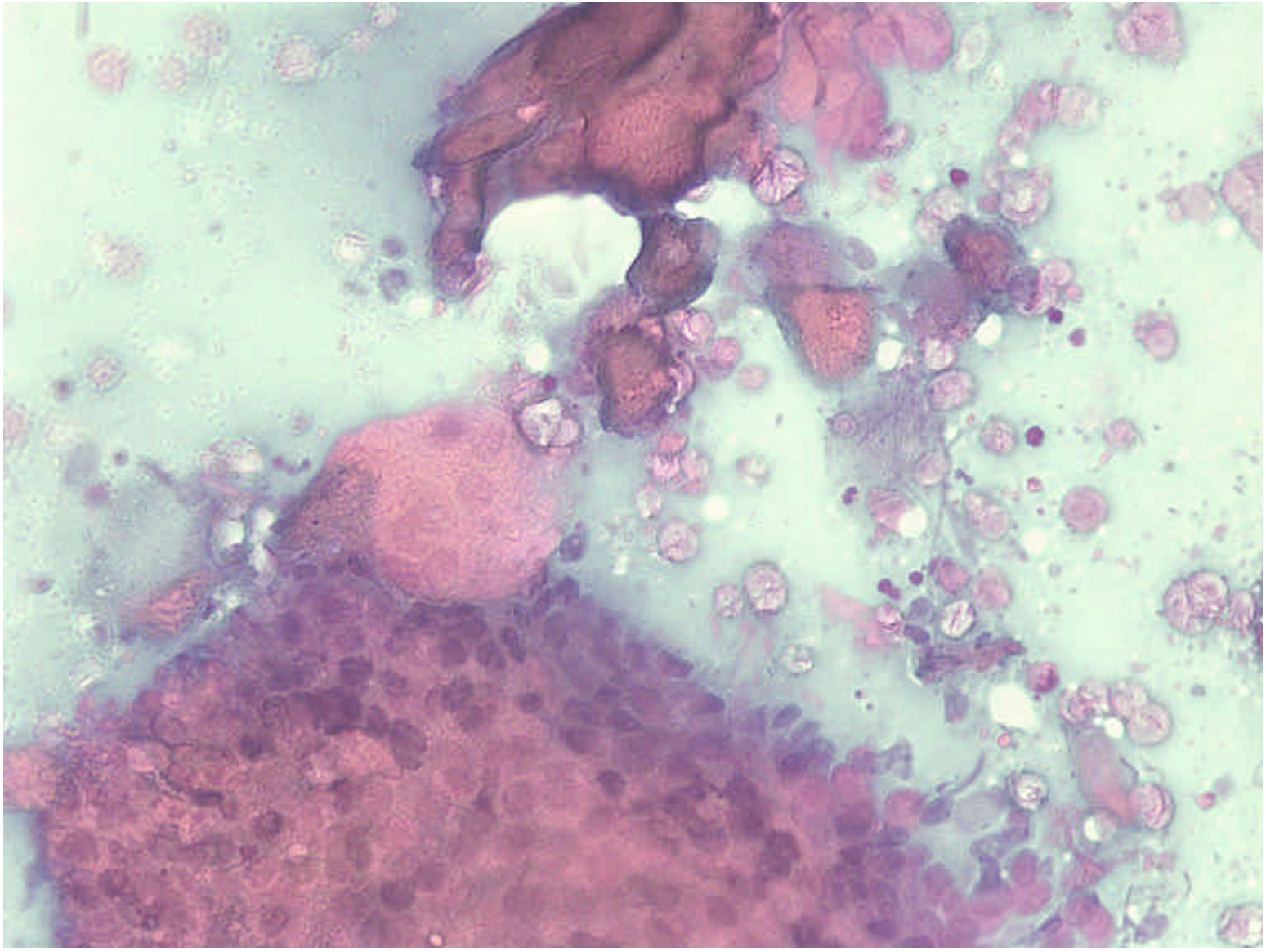

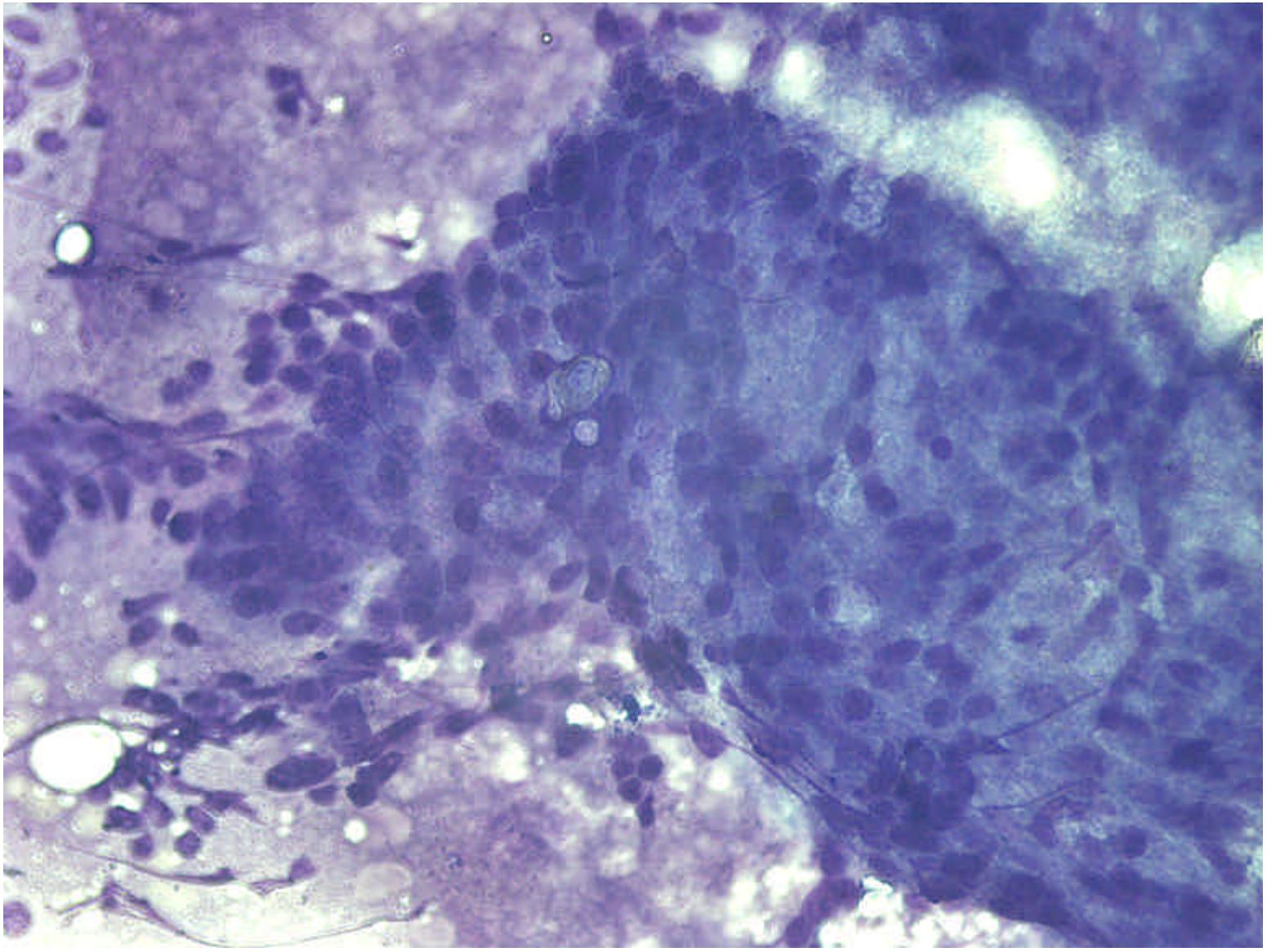

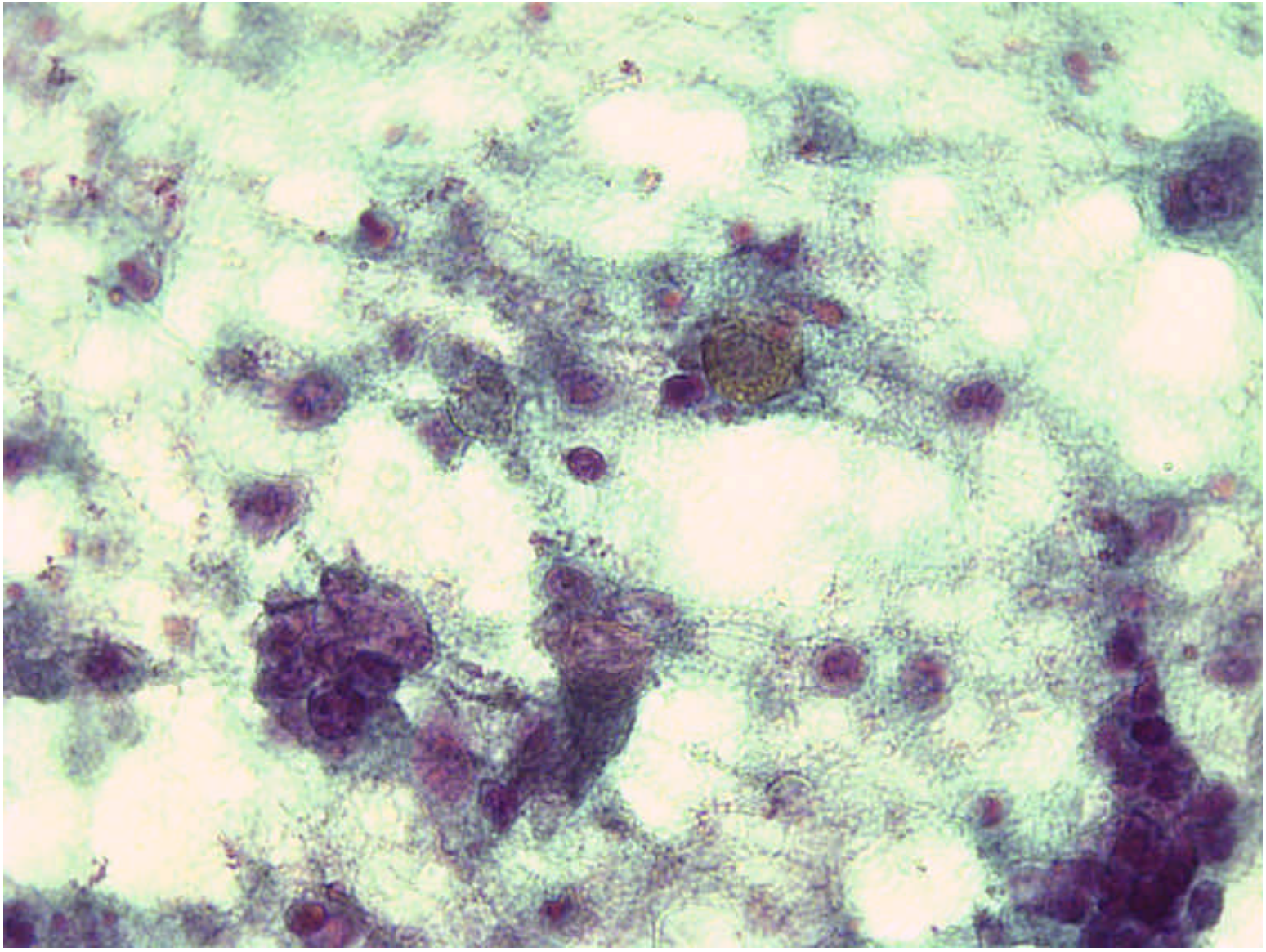

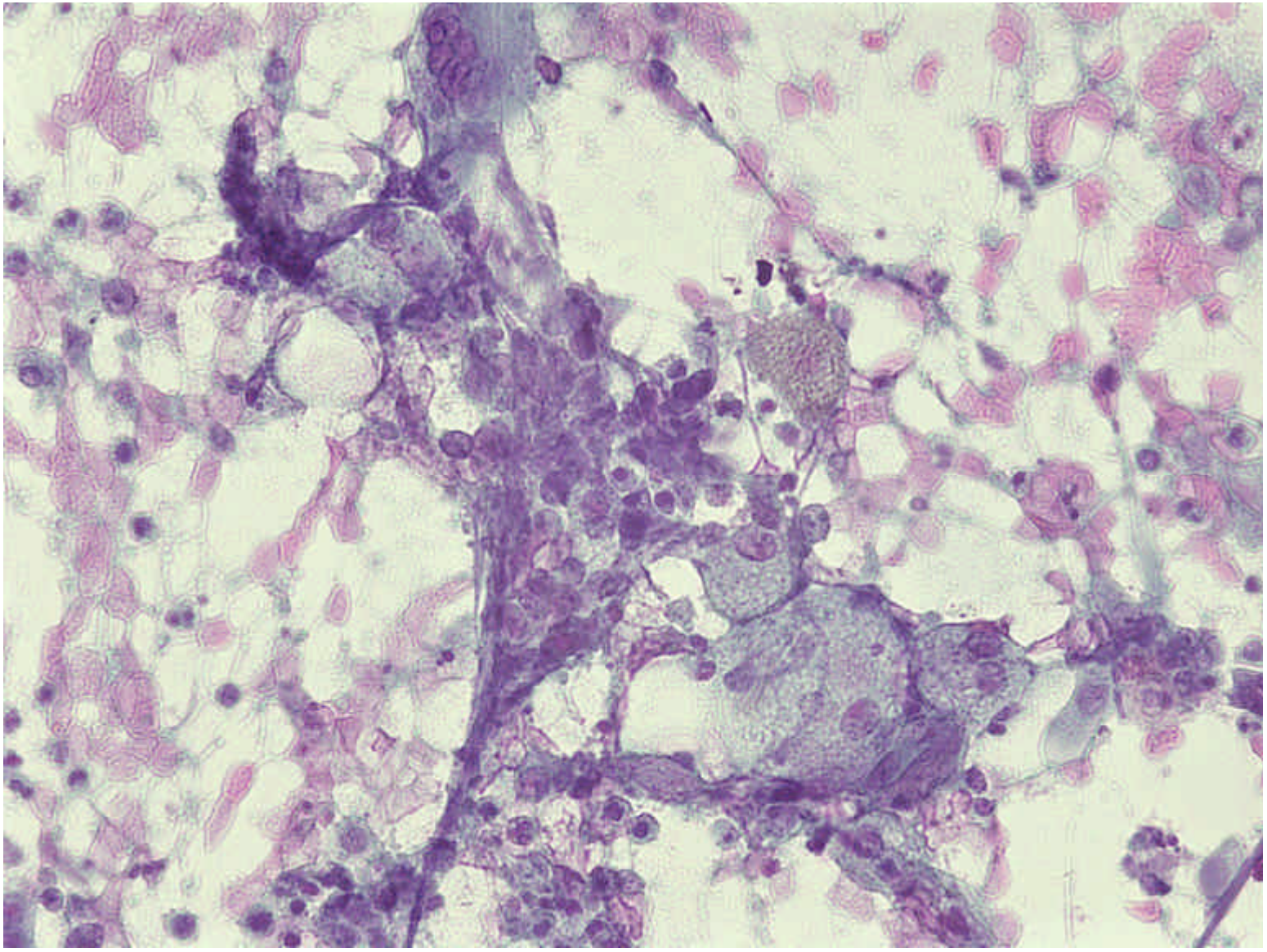

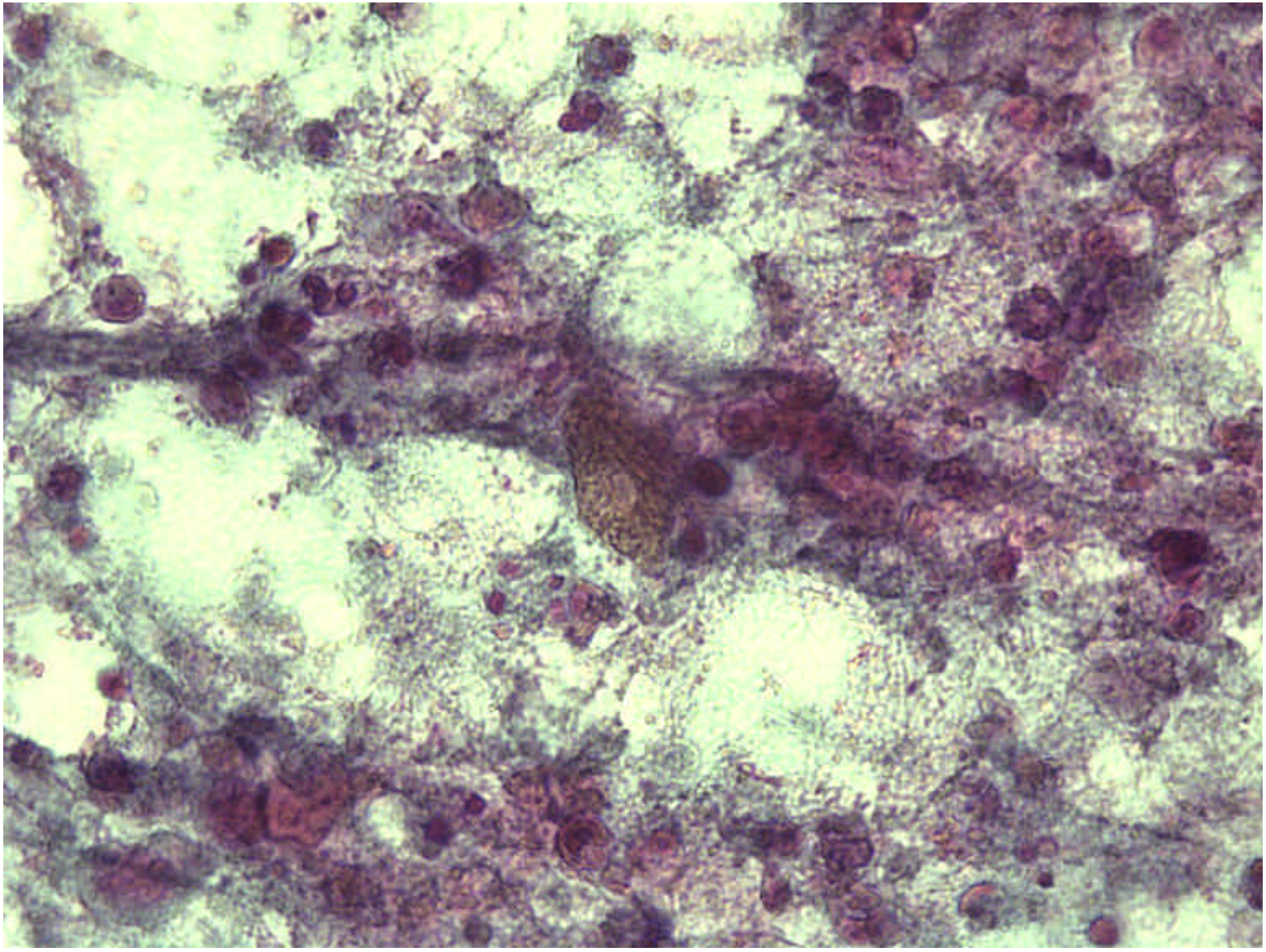

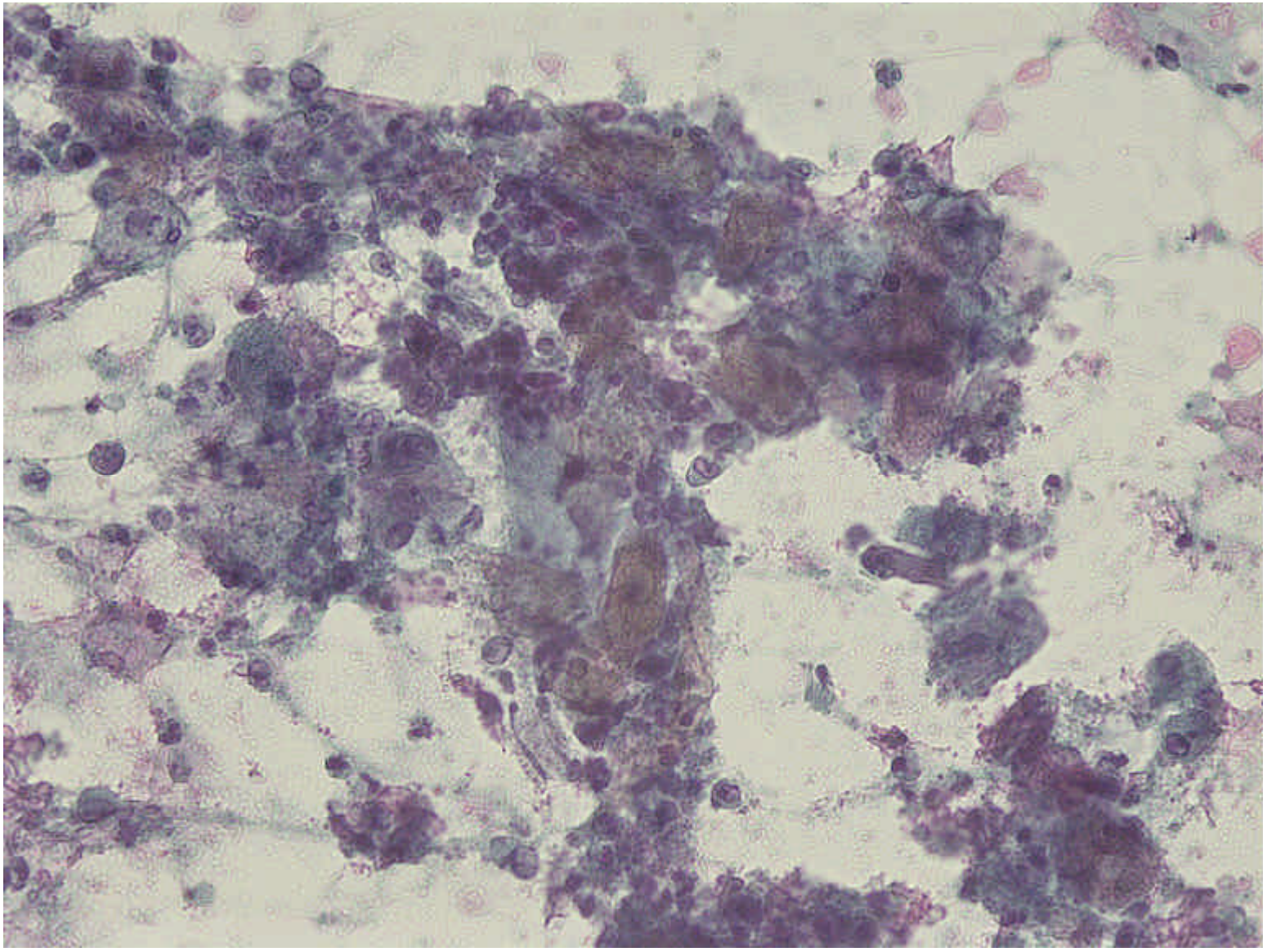

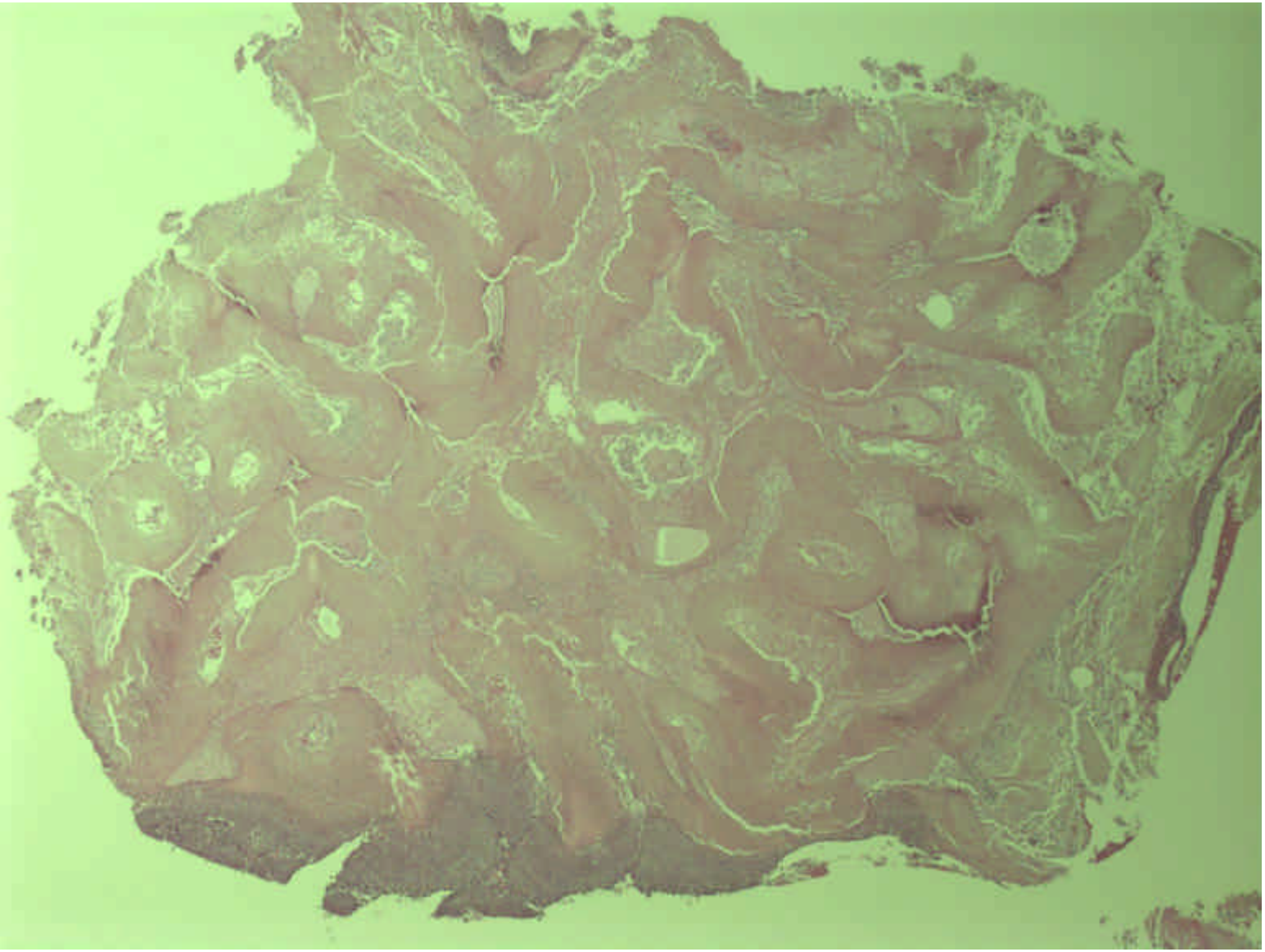

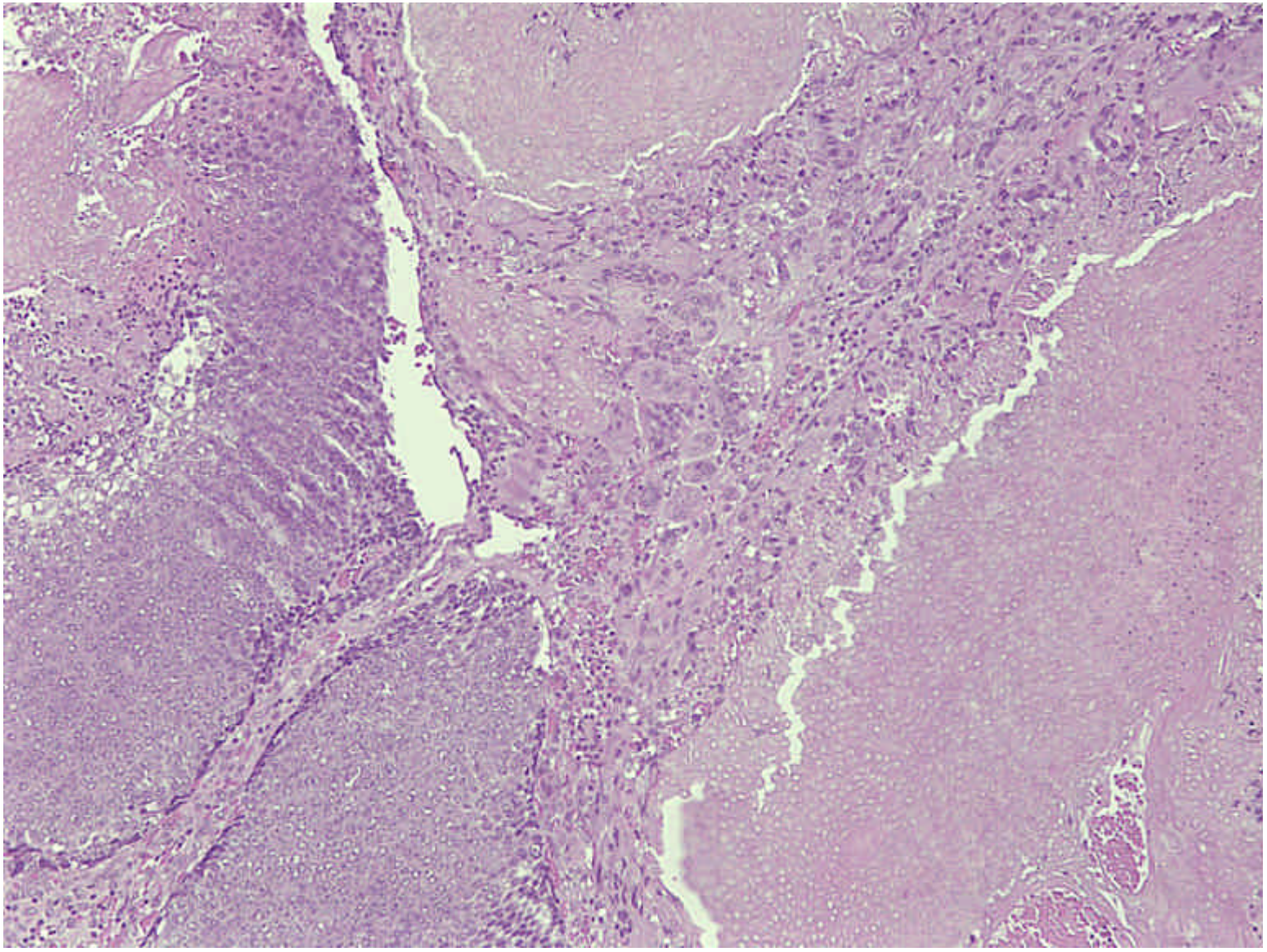

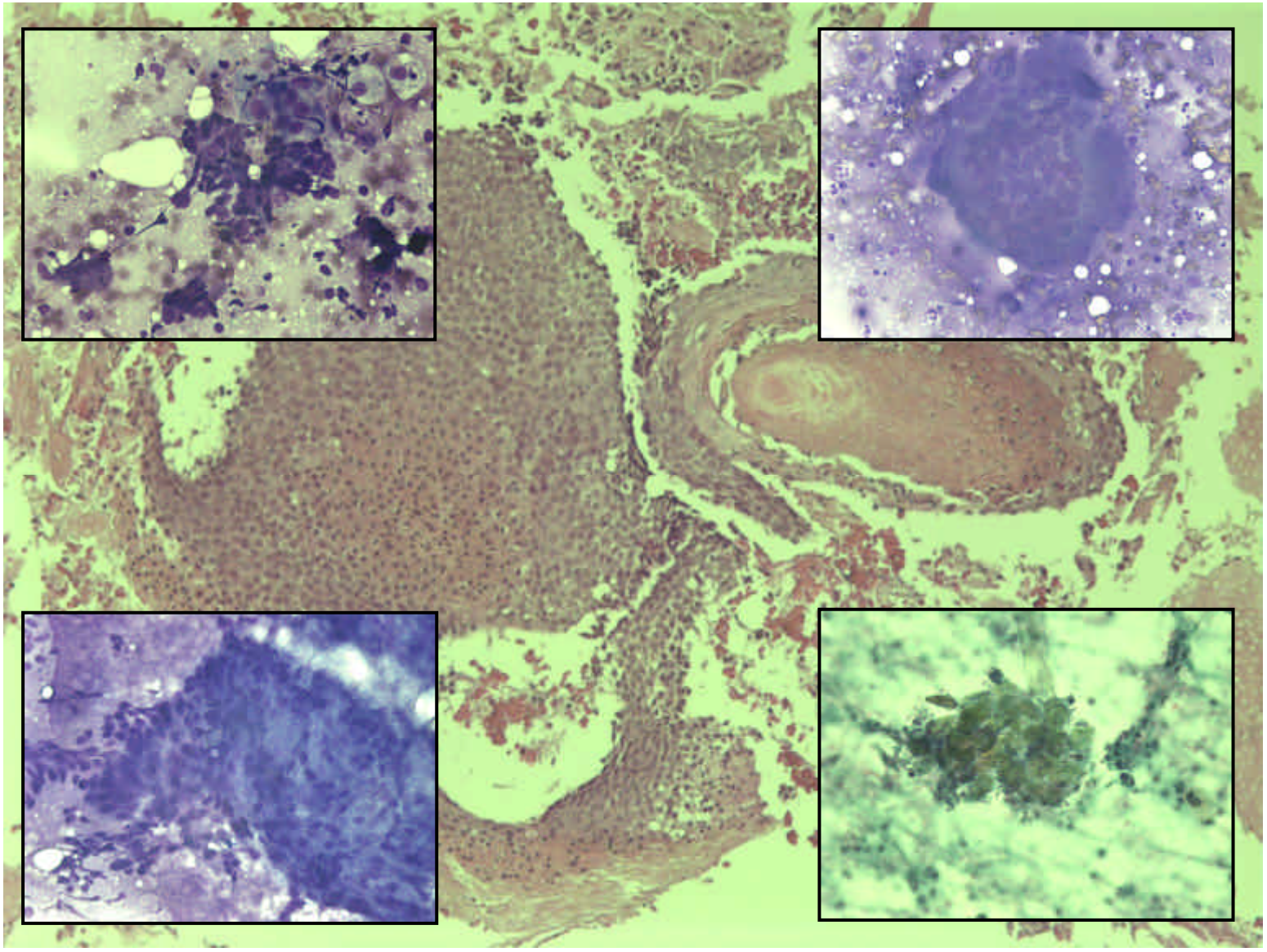

Acta Cytol 1997 May-Jun;41(3):771-777

- 9 casos de pilomatricoma+PAAF previa:
  - Fondo inflamatorio con restos celulares 9:9
  - Células basaloides: 9:9
  - Células fantasma y calcio: 6:9
  - Células gigantes multinucleadas: 5/9

Diagnóstico de pilomatricoma en citología

- Anexial con dif matricial
  - 60% en primeras dos décadas
  - Cabeza y cuello y EESS

No tan fácil

- Falsos positivos con carcinomas primitivos y metastásicos:
  - Basocelular, escamoso, anexiales, Merkel, Oat cell, ca nasofaríngeo…
  - Localización:
    - Ca de mama, ca mucoepidermoide
  - Citología:
    - Grupos tridimensionales, células basales, pérdida de cohesividad, fondo necrótico, atipia, mitosis…
    - Células fantasma no siempre presentes.
- Foro de diagnóstico por imagen:
  - 2:8 diagnosticaron pilomatricoma