

## Virtual Slide Congress. Case # 08

- Slides Index

- Home

Mercedes García Villanueva\*, María García Martos\*, M<sup>a</sup> Eugenia Reguero Callejas\*

\* Hospital Ramón y Cajal. Madrid ESPAÑA

- Top

- Virtual Slide  
- Clinical history  
- Pathology diagnosis  
- Pathology findings  
- References

### Clinical history

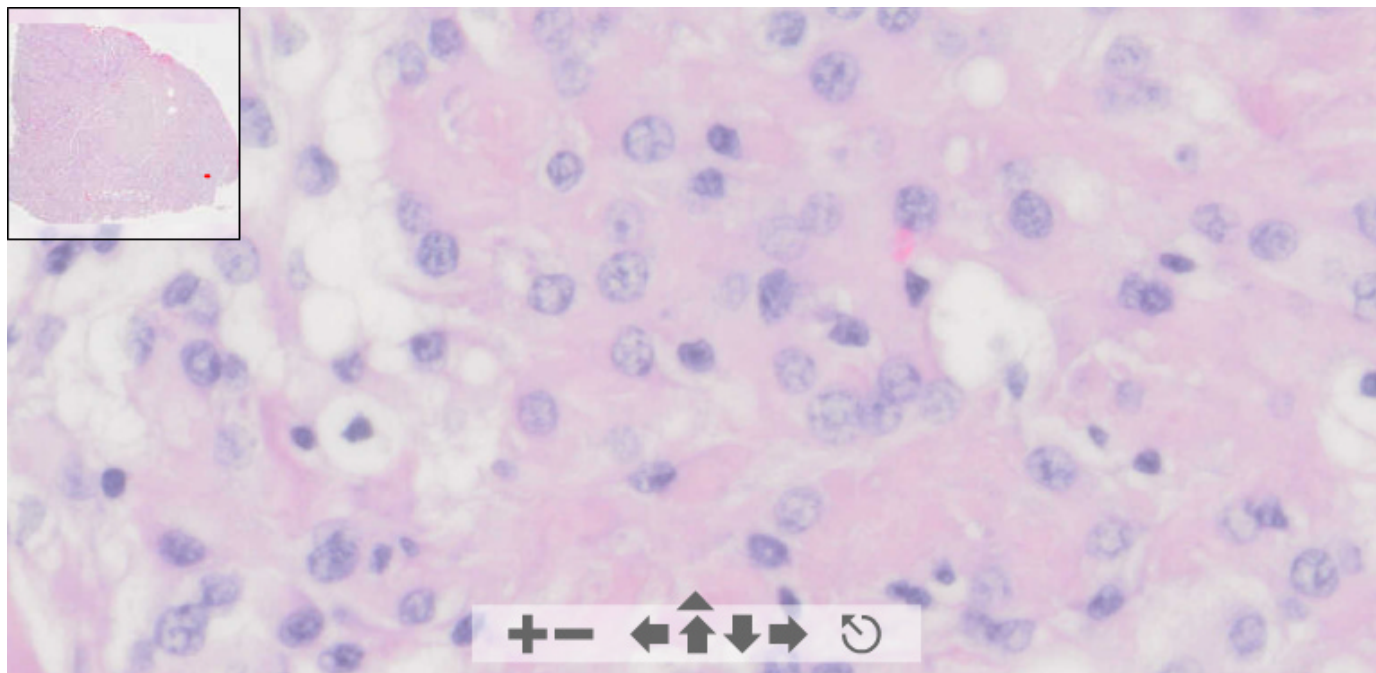
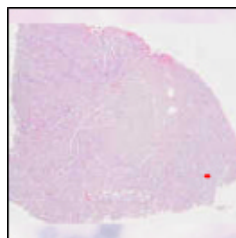
Female 22 years old presented a back pain and left leg weakness of 8 months of evolution.

Magnetic resonance imaging revealed an intradural extramedullary tumour at L1-L2 which displaced spinal roots to the left.

# OLYMPUS

Your Vision, Our Future

This slide's been digitized with **Olympus/SIS dotslide system**  
Preparación digitalizada con el sistema **Olympus/SIS dotslide**  
**H&E**

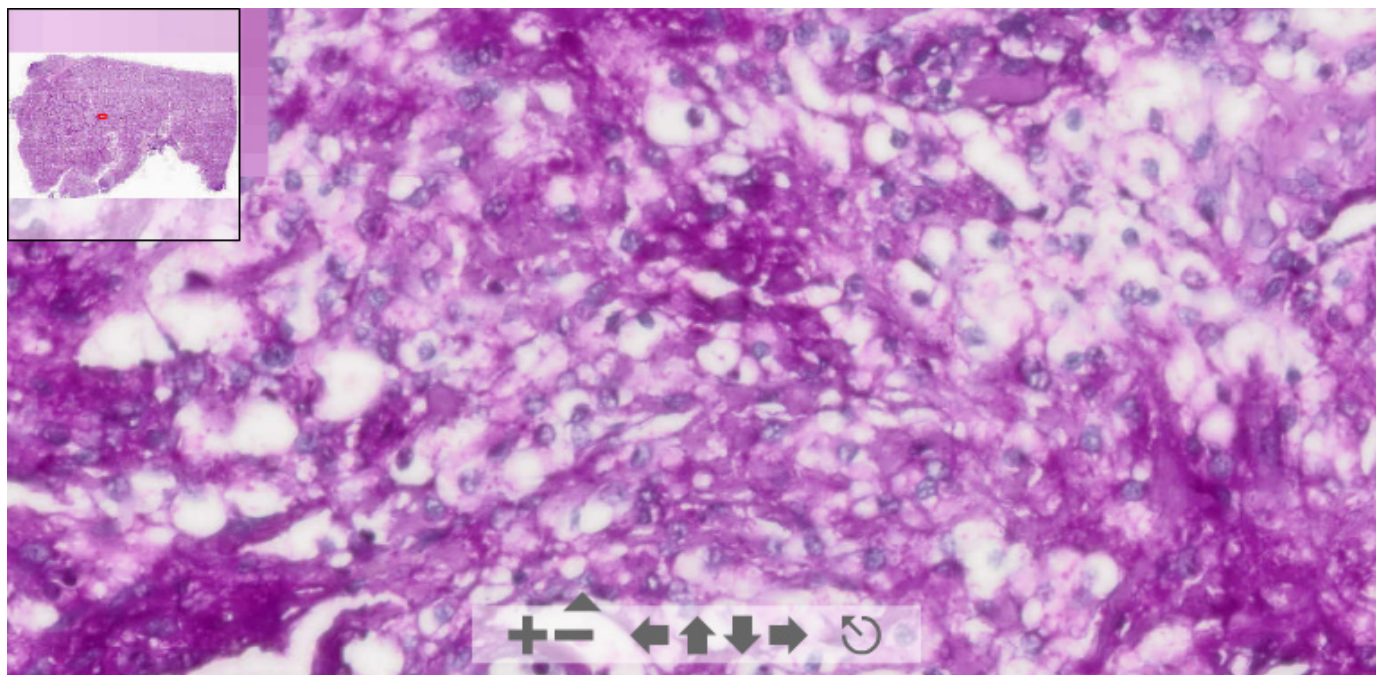


(See virtual slide in full window size- *Ver preparación en ventana completa*)

# OLYMPUS

Your Vision, Our Future

This slide's been digitized with **Olympus/SIS dotslide system**  
Preparación digitalizada con el sistema **Olympus/SIS dotslide**  
**PAS**

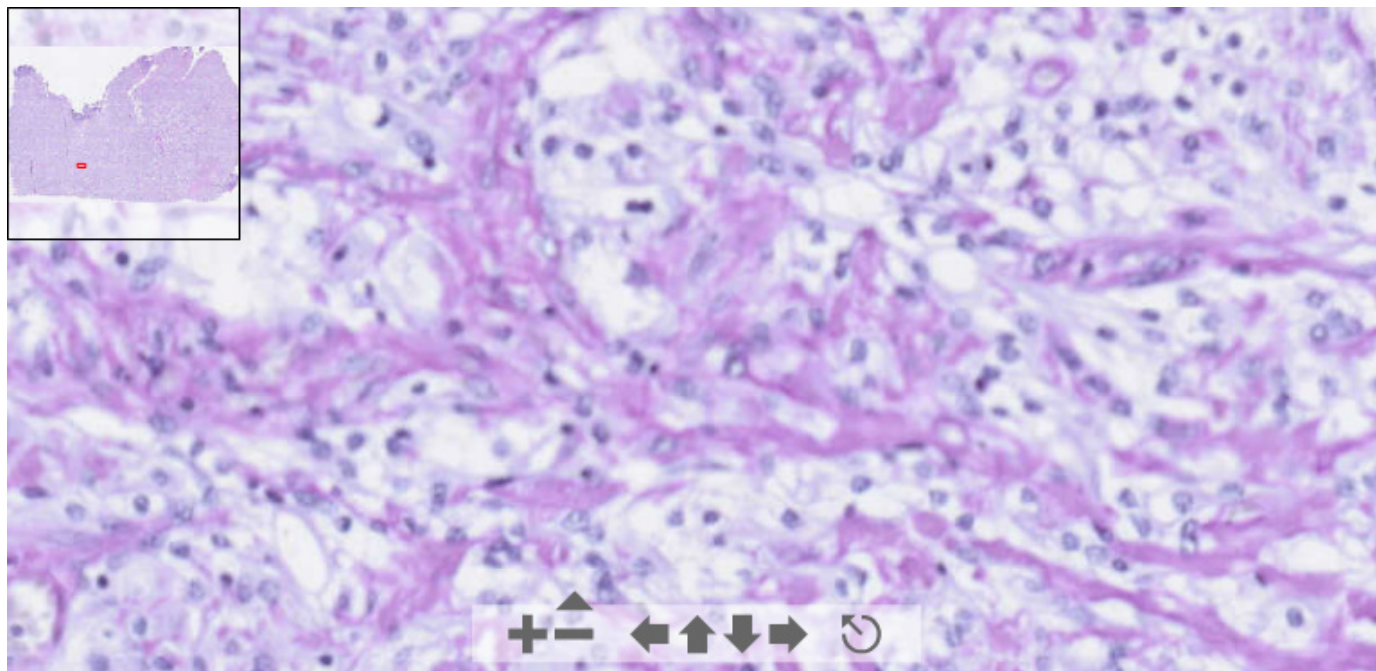


(See virtual slide in full window size- *Ver preparación en ventana completa*)

**OLYMPUS**

Your Vision, Our Future

This slide's been digitized with **Olympus/SIS dotslide system**  
Preparación digitalizada con el sistema **Olympus/SIS dotslide**  
**PAS-D**



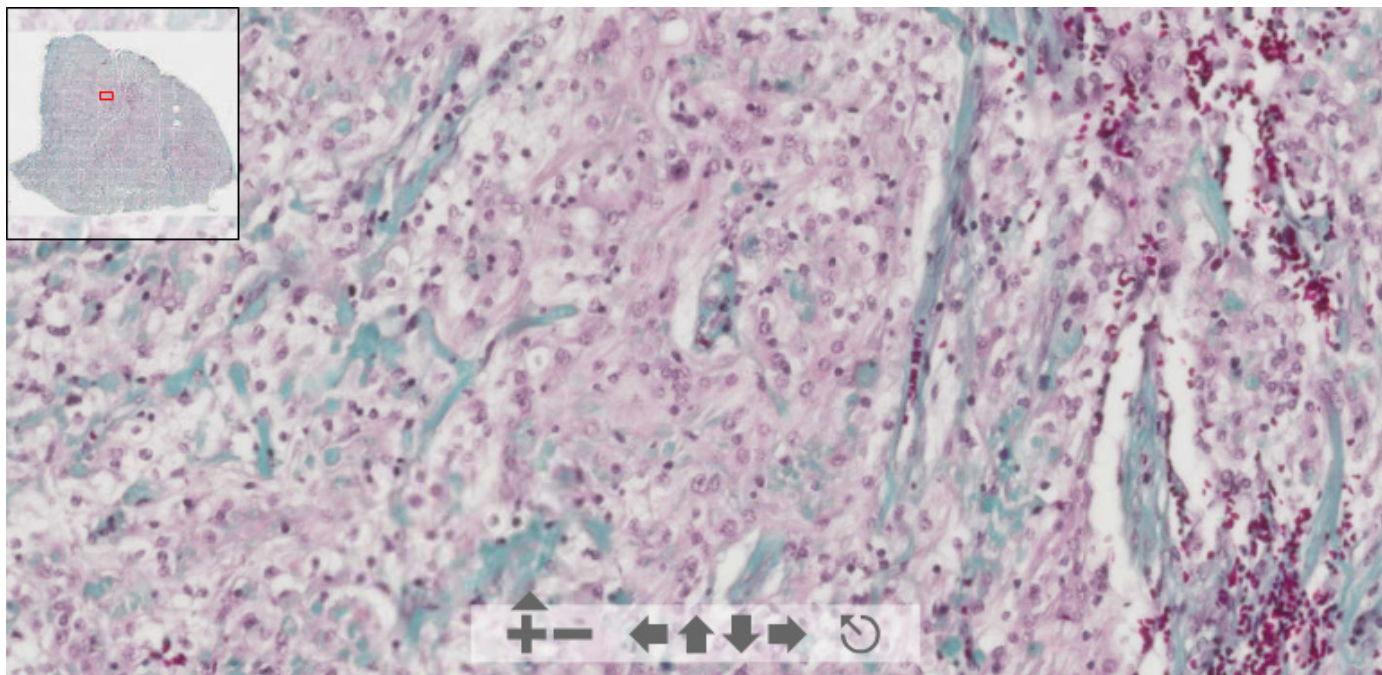
(See virtual slide in full window size- *Ver preparación en ventana completa*)

**OLYMPUS**

This slide's been digitized with **Olympus/SIS dotslide system**  
Preparación digitalizada con el sistema **Olympus/SIS dotslide**



## Masson

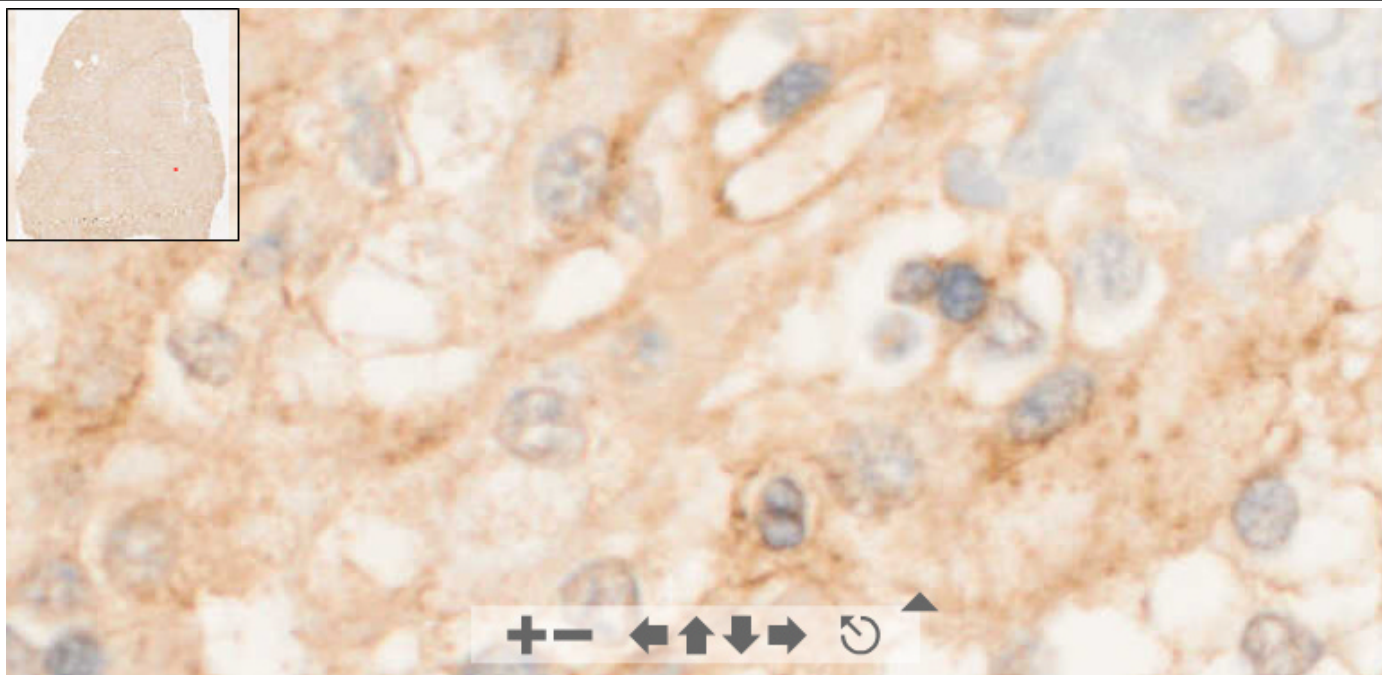


(See virtual slide in full window size- *Ver preparación en ventana completa*)

**OLYMPUS**

Your Vision, Our Future

This slide's been digitized with **Olympus/SIS dotslide system**  
Preparación digitalizada con el sistema **Olympus/SIS dotslide**  
**EMA**

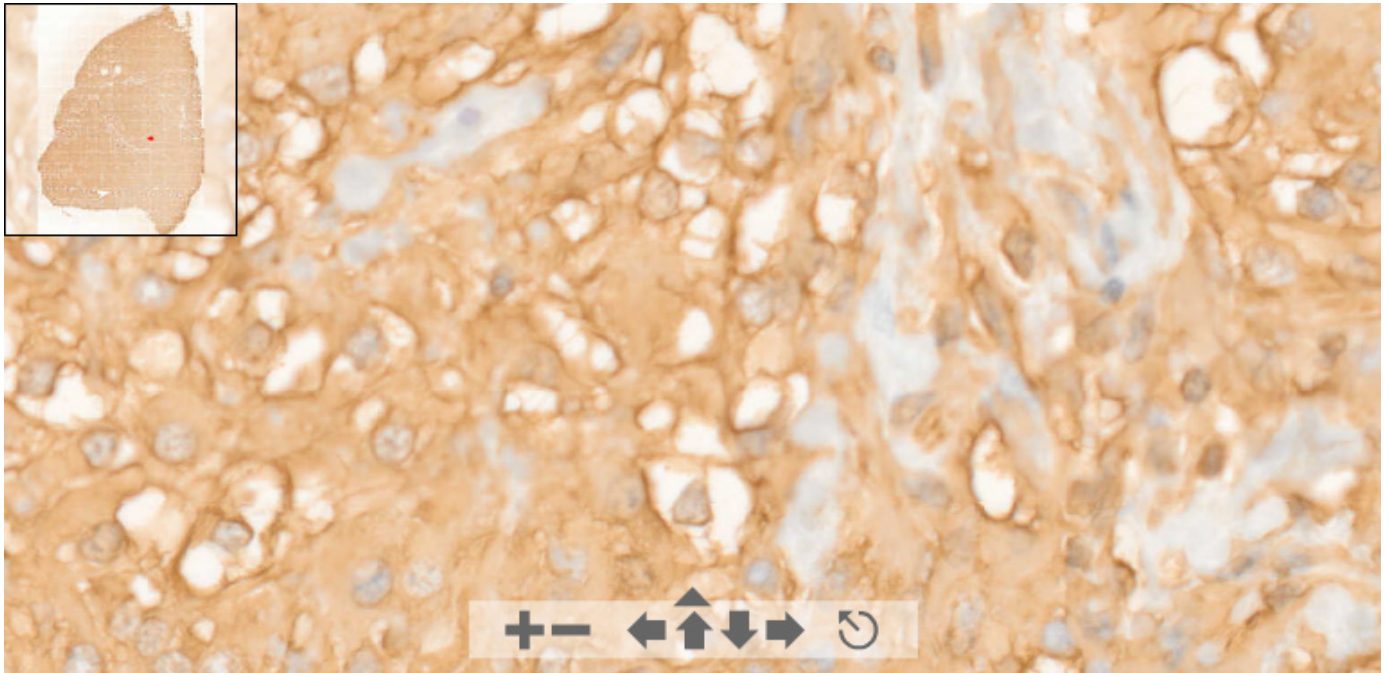


(See virtual slide in full window size- *Ver preparación en ventana completa*)

**OLYMPUS**

Your Vision, Our Future

This slide's been digitized with **Olympus/SIS dotslide system**  
 Preparación digitalizada con el sistema **Olympus/SIS dotslide**  
**Vimentin**



(See virtual slide in full window size- *Ver preparación en ventana completa*)

- Top

- Virtual Slide  
 - Clinical history  
 - Pathology diagnosis  
 - Pathology findings  
 - References

**Diagnosis**

- Clear cell meningioma (Meningioma de células claras)
- Schwannoma
- Neurofibroma
- Ependymoma (Ependimoma)
- Drop metastasis from a pineoblastoma (Metástasis de pinealoblastoma)

**FINAL DIAGNOSIS IS BELOW THIS LINE**

- Top

- Virtual Slide  
 - Clinical history  
 - Pathology diagnosis  
 - Pathology findings  
 - References

**Pathology diagnosis**

CLEAR CELL MENINGIOMA

- Top

- Virtual Slide  
 - Clinical history  
 - Pathology diagnosis  
 - Pathology findings  
 - References

**Pathology findings****MAIN PATHOLOGIC FINDINGS**

Histologically the tumour showed sheets of cells having clear polygonal cytoplasm rich in glycogen, with round, uniform and bland-appearing nuclei without mitosis. No whorls, clear cytoplasmic inclusions or psammomatous bodies were observed. The stroma displayed prominent collagen bundles of varying size, closely associated with the tumour cells.

Immunohistochemically, the tumour cells were positive for vimentin and epithelial membrane antigen and negative for cytokeratin, S-100 and glial fibrillary acidic protein.

<p><a href="#">- Top</a></p> <ul style="list-style-type: none"><li><a href="#">- Virtual Slide</a></li><li><a href="#">- Clinical history</a></li><li><a href="#">- Pathology diagnosis</a></li><li><a href="#">- Pathology findings</a></li><li><a href="#">- References</a></li></ul>	<h2>References</h2> <p>-Liu PI, Liu GC., Tsai KB, Lin CL, Hsu JS. <i>Intraspinal clear-cell meningioma: case report and review of literature</i>. Surg Neurol 2005; 63:285-8.</p> <p>- Oviedo A., Pang D., Zovickian J., Smith M. <i>Clear cell meningioma: case report and review of the literature</i>. Pediatr Dev Pathol 2005; 8:386-90.</p> <p>- Carlotti CG , Neder L, Colli BO, dos Santos MB, García AS, Elías J, Chimelli LC. <i>Clear cell meningioma of the fourth ventricle</i>. Am J Surg Pathol 2003; 27:131-135.</p>
<p><a href="#">- Top</a></p> <ul style="list-style-type: none"><li><a href="#">- Virtual Slide</a></li><li><a href="#">- Clinical history</a></li><li><a href="#">- Pathology diagnosis</a></li><li><a href="#">- Pathology findings</a></li><li><a href="#">- References</a></li></ul>	<h2>Comments</h2> <p>- <b>Ernesto Blanco Blanco</b> (29/10/2005 12:23:22)</p> <p>Realmente una rareza, sobre todo la localización. Las células claras recuerdan un poco las del seminoma. Felicidades!!!</p> <p>- <b>Mirta Garcia Jardón</b> (29/10/2005 13:47:08)</p> <p>Congratulations for such interesting case. We have had one recently but of angiomatous variant.</p> <p>- <b>Javier Muñoz Moreno</b> (31/10/2005 13:38:58)</p> <p>Raro e interesante. Felicidades.</p> <p>- <b>HUGO GÓNGORA JARA</b> (09/11/2005 3:49:44)</p> <p>Muy interesante. Llama la atención la presencia de linfocitos. Felicidades.</p> <p>- <b>LILIA MARGARITA BERNAL MONDRAGÓN</b> (11/11/2005 7:14:58)</p> <p>Precioso caso; encontré una calcosfera, lo que aunado a los nidos de células claras me ayudo sustancialmente a establecer el diagnóstico.</p>