

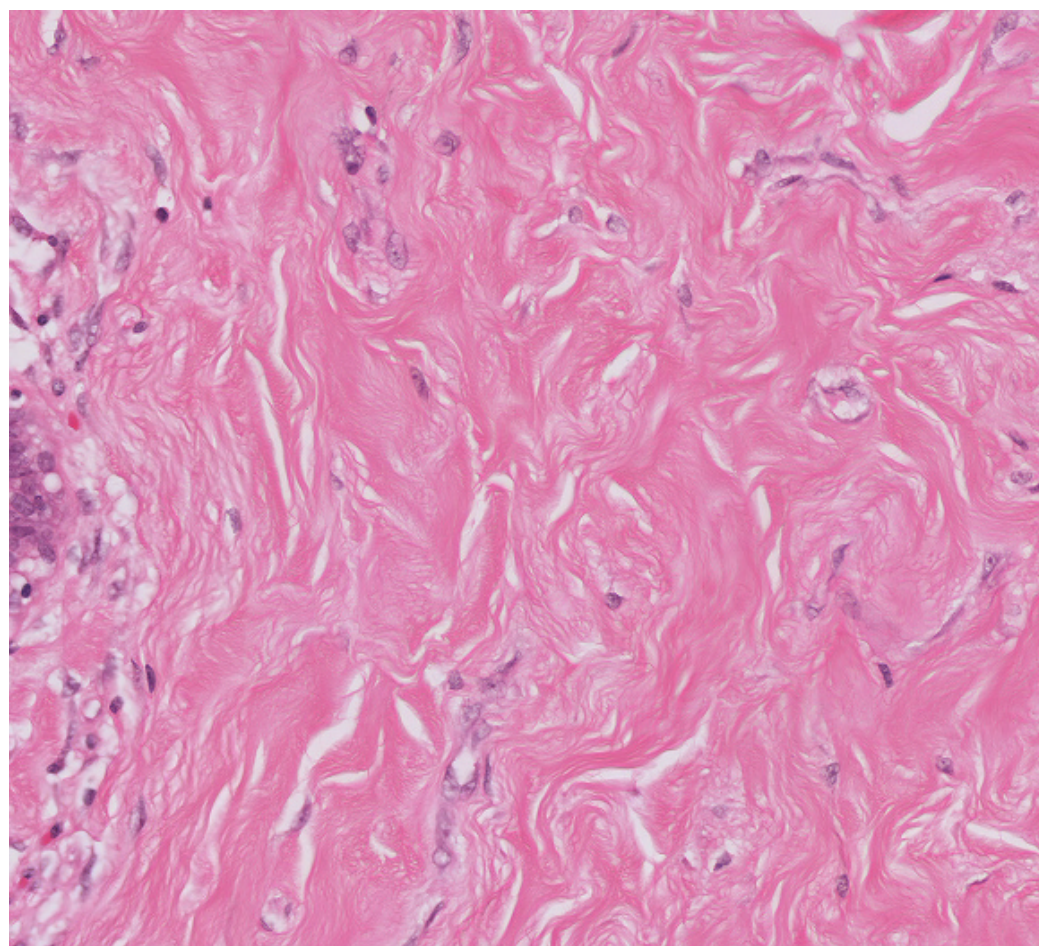
## Virtual Slide Congress. Case # 12

<ul style="list-style-type: none"> <li>- Slides Index</li> <li>- Home</li> </ul>	<p>M<sup>a</sup> Dolores Arias Santos<sup>*</sup>, Marta Pavcovich Ruiz<sup>*</sup>, Concepción Jiménez<sup>**</sup>, Carmen Busto Ferrer<sup>***</sup>, Miguel Andújar Sánchez<sup>*</sup>, Miguel Sánchez Ramos<sup>*</sup></p> <p><i>* Patología. Hospital Materno Infantil Canarias ESPAÑA</i>  <i>** Ginecología. Hospital Materno Infantil Canarias ESPAÑA</i>  <i>*** Radiología. Hospital Materno Infantil Canarias ESPAÑA</i></p>
<ul style="list-style-type: none"> <li>- Top</li> <li>- Virtual Slide</li> <li>- Clinical summary</li> <li>- DIAGNOSIS</li> <li>- Discussion</li> <li>- References</li> </ul>	<p><b>Clinical summary</b></p> <p>Female, 40 y.o. with a breast lump.              It was an unilateral, non painful rounded nodule, well delimited and mobile.</p> <p>It had a clinical and radiological fibroadenoma appearance.</p> <hr/> <p><b>Historia clínica:</b>              Mujer de 40 años con nódulo de mama. Es unilateral, no doloroso, redondeado, bien delimitado y móvil.</p> <p>Aspecto tanto clínico como mamográfico de fibroadenoma.</p>



**WebMicroscope**

This slide's been kindly digitized by [WebMicroscope's team \(Finland\)](#)  
 Preparación amablemente digitalizada por los responsables de [WebMicroscope \(Finlandia\)](#)



Hand icon
Search icon
Zoom icon
Reset icon

2x
5x
10x
20x
40x

Contrast: 1.00 Reset

Brightness: 1.00 Reset

Case 12, C12 (x40)  
 Regions of Interest: [On/Off](#)



See virtual slide in full window size - [Ver caso en Webmicroscope](#)

- Top
- Virtual Slide
- Clinical summary
- DIAGNOSIS
- Discusion
- References

## Diagnosis

- Pseudoangiomatous stromal hyperplasia, PASH (Hiperplasia estromal pseudoangiomatosa de mama)
- Fibroadenoma
- Diffuse Angiomatosis (Angiomatosis difusa)
- Low grade Angiosarcoma (Angiosarcoma de bajo grado)
- Fibrocystic disease (Enfermedad fibroquística)

**FINAL DIAGNOSIS IS BELOW THIS LINE**

- Top
- Virtual Slide
- Clinical summary
- DIAGNOSIS
- Discusion
- References

## DIAGNOSIS

Pseudoangiomatous stromal hyperplasia (PASH)  
(*Hiperplasia estromal pseudoangiomatosa de mama*)

- Top
- Virtual Slide
- Clinical summary
- DIAGNOSIS
- Discusion
- References

## Discusion

See paper presented at the [7th Virtual Hispano-American Congress of Pathology](#).

- Top
- Virtual Slide
- Clinical summary
- DIAGNOSIS
- Discusion
- References

## References

See paper presented at the [7th Virtual Hispano-American Congress of Pathology](#).

- Top
- Virtual Slide
- Clinical summary
- DIAGNOSIS
- Discusion
- References

## Comments

- **Alexandra Gené Heym** (24/10/2005 15:46:27)

Very interesting case. Congratulations.  
*Caso muy interesante. Enhorabuena.*

- **Mirta Garcia Jardon** (29/10/2005 13:22:28)

What is the point in repeating the cases in the same congress?

- **Marcial García Rojo** (29/10/2005 20:35:25)

This is an uncommonly diagnosed pathology, and we have the opportunity of reviewing different cases to make a better idea with these samples. I think they are a perfect complement to [the paper presented at the 7th Virtual Hispano-American Congress of Pathology \(see Breast/Mama section\)](#). Thanks to the authors.

- **HUGO GÓNGORA JARA** (04/11/2005 22:35:53)

It is a good idea to present this case in this virtual slide model, and not only as digital photography. Using it, we can explore the whole specimen. Thanks for showing it  
*Esta muy bueno al presentar este caso en este modelo de microscopio virtual y no solo de fotografías digitales. Uno puede explorar todo el preparado. Gracias por presentarlo.*