

Virtual Slide Congress. Case # 04

- Slides Index

- Home

Beatriz Di Martino Ortiz*, Mirtha Rodríguez Masi*, Raquel Názer Da Silva*, Liz Flor*, Oilda Knopfmacher*, Lourdes Bolla*

* Servicio de Dermatología. Hospital de Clínicas. Asunción PARAGUAY

- Top

- Virtual Slide
- Clinical summary
- DIAGNOSIS
- Pathology
- References

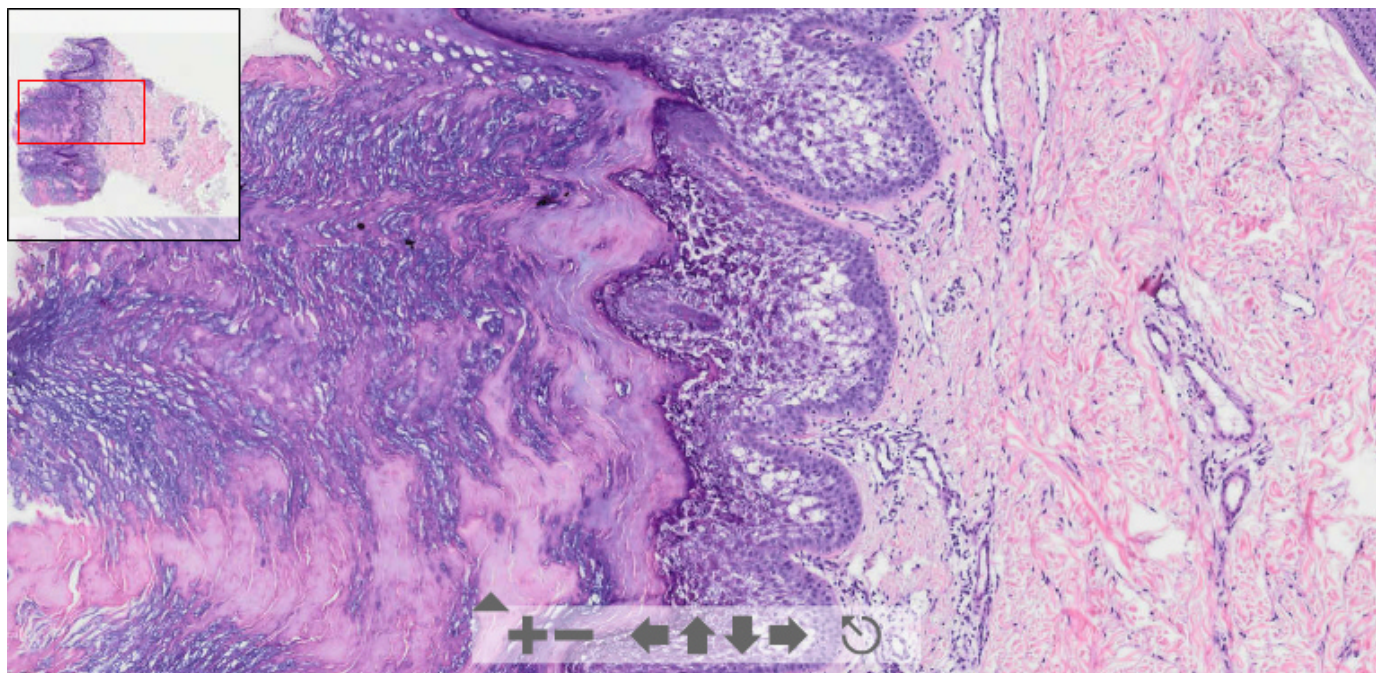
Clinical summary

5- year- old white male with multiple and large warty brown plaques with bilateral distribution on the neck, trunk and axillary region.

OLYMPUS

Your Vision, Our Future

This slide's been digitized with **Olympus/SIS dotslide system**
Preparación digitalizada con el sistema **Olympus/SIS dotslide**



(See virtual slide in full window size- Ver preparación en ventana completa)

- Top

- Virtual Slide
- Clinical summary
- DIAGNOSIS
- Pathology
- References

Diagnosis

- Epidermal Nevus with Epidermolytic Hyperkeratosis (Nevus epidérmico con hiperqueratosis epidermolítica)
- Acantholytic Acanthoma (Acanthoma acantolítico)
- Congenital bullous ichthyosiform Erythroderma (Eritrodermia ictiosiforme ampollar congénita)
- Verrucous syndrome (Síndrome verrucoso)

FINAL DIAGNOSIS IS BELOW THIS LINE

- Top
- Virtual Slide
- Clinical summary
- **DIAGNOSIS**
- Pathology
- References

DIAGNOSIS

ICHTHYOSIS HYSTRIX (GENERALIZED EPIDERMAL NEVI) ASSOCIATED WITH EPIDERMOLYTIC HYPERKERATOSIS

- Top
- Virtual Slide
- Clinical summary
- **DIAGNOSIS**
- Pathology
- References

Pathology

Main pathologic findings: acanthosis, papillomatosis and compact hyperkeratosis. Clear spaces around the nuclei of the cells of upper stratum spinosum and in the stratum granulosum. Indistinct cellular boundaries peripheral to these clear spaces. Thickened of the granular layer and increased number of keratohyaline granules. Chronic inflammatory infiltrate in the upper dermis.

Additional information is available at the paper in the "[7th Virtual Hispano-American Congress of Pathology](#)"

Figure 1

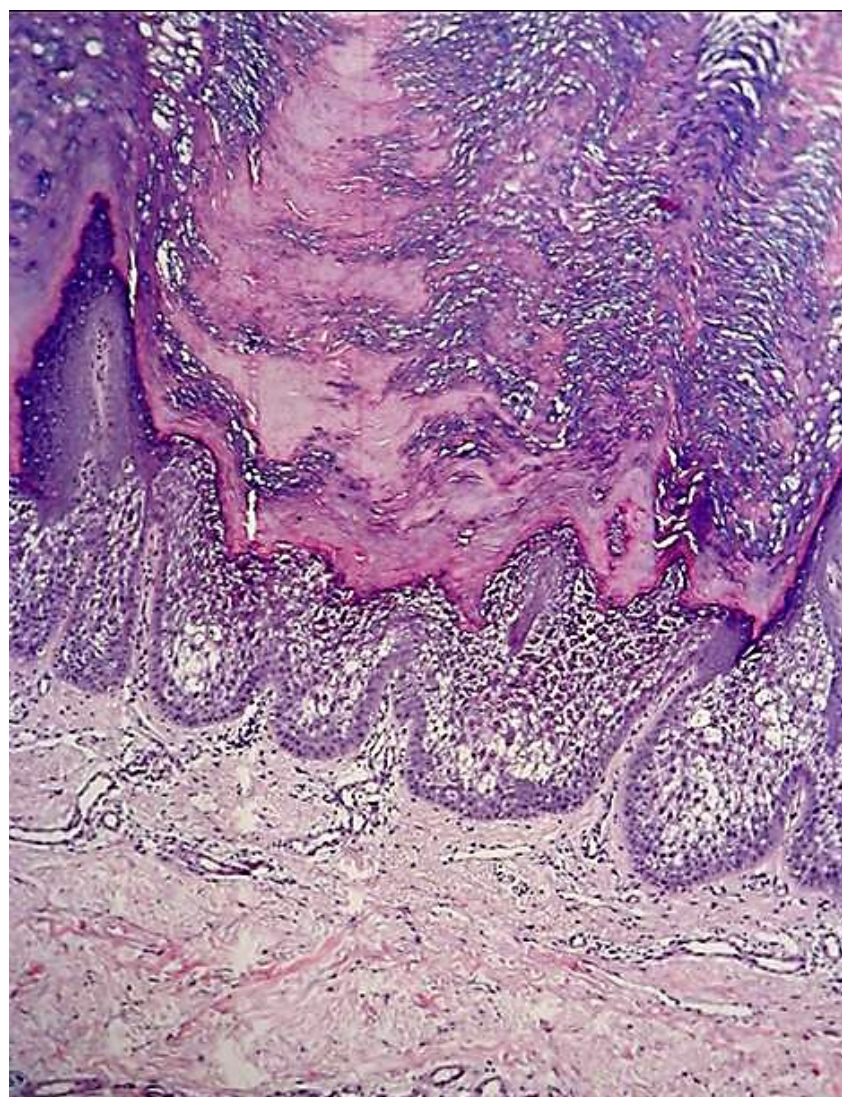
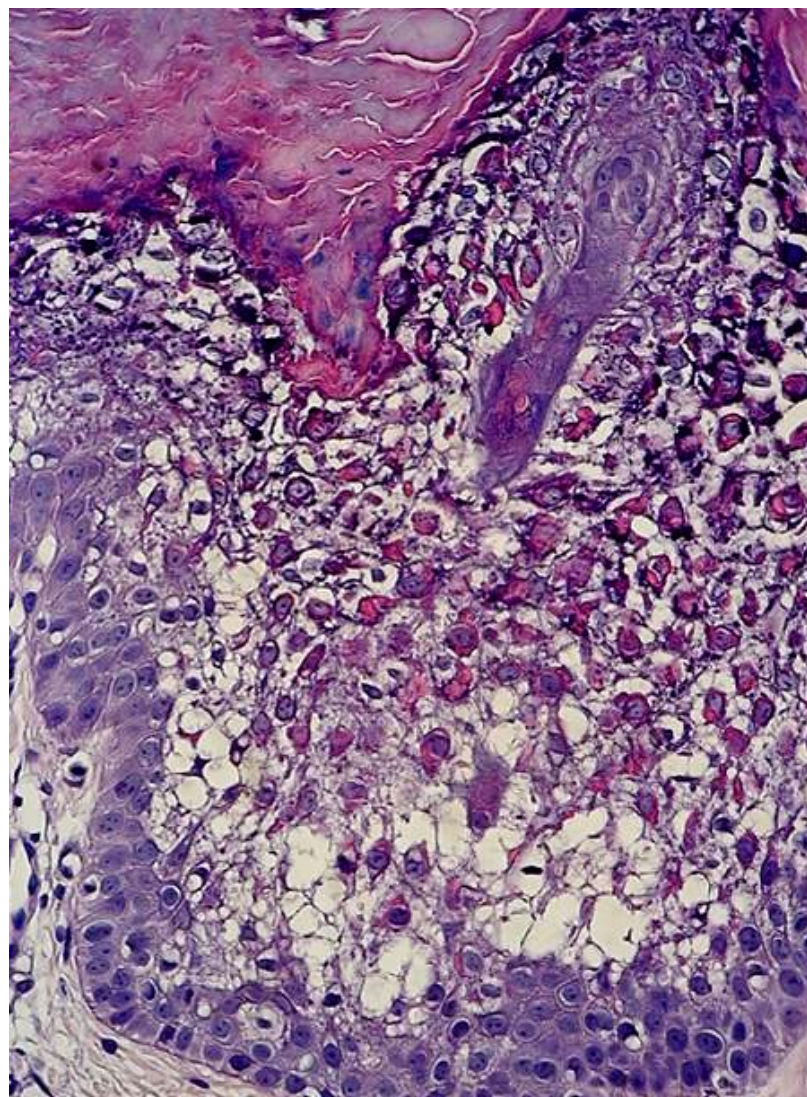


Figure 2



- Top
- Virtual Slide
- Clinical summary
- DIAGNOSIS
- Pathology
- References

References

- 1 - Sánchez Yus E, Martín-Dorado E, López Negrete E. Incidental epidermolytic hiperqueratosis. An epidemiologic study. *Am J Dermatopathol* 2000;22:352.
- 2 - Niemi KM, Virtanen I, Kanerva L, Muttillainen M. Altered keratin expression in ichthyosis hystrix Curth-Macklin. A light and electron microscopic study. *Arch Dermatol Res*. 1990;282(4):227-33.
- 3 - Sprecher E, Yosipovitch G, Bergman R, Ciubutaro D, Indelman M, Pfindner E, Goh LC, Miller CJ, Uitto J, Richard G. Epidermolytic hyperkeratosis and epidermolysis bullosa simplex caused by frameshift mutations altering the v2 tail domains of keratin 1 and keratin 5. *J Invest Dermatol*. 2003 Apr;120(4):623-6.

- Top
- Virtual Slide
- Clinical summary
- DIAGNOSIS
- Pathology
- References

Comments

- **JORGE SAINZ BALLESTEROS** (04/10/2005 15:57:24)

A very interesting and web illustrated case. Congratulations to the authors
Caso muy interesante y muy bien ilustrado. Felicidades a los autores
 Dr. Jorge Sainz. Cuba

- **Cesáreo Corbacho Cuevas** (04/10/2005 17:52:40)

I've learned a lot with this case. Many thanks.
Un caso con el que he aprendido mucho. Muchísimas gracias.

- María Caridad De Armas Fernández (04/10/2005 18:09:56)

Very interesting case. Microphotographies a very demonstratives. I congratulate the submitting authors. Thanks a lot.
caso muy interesante. Las microfotografías están muy demostrativas. Felicito a los que enviaron el caso. Muchas gracias.

- David Cubero Rego (04/10/2005 23:50:24)

Very interesting case
Caso muy interesante.

- hector santiago antunez moncada (05/10/2005 8:06:11)

In 1978, Basler y Jacobs called this condition ictiosis histrix, unnecessarily
Basler y Jacobs en 1978 llamaron a esta condición ictiosis histrix innecesariamente

- Juan Pablo Garcia de la Torre (05/10/2005 8:50:29)

A very interesting case with very representative epidermolysis image. The existence of multiple lesions is noticeable
Un caso muy interesante con imagen muy representativa de epidermolisis. Es curioso y destacable la presencia de múltiples lesiones.

- MARIBEL ALTAGRACIA DONASTORG VITTINI (06/10/2005 14:44:48)

Epidermolysis is interesting. I didn't think of it. Very interesting, and also the fact of being multiple lesions.
Interesante la epidermolisis. No lo pensé. Muy interesante, y que sea múltiples lesiones.
Maribel Donastorg

- Javier Muñoz Moreno (24/10/2005 13:18:52)

It is interesting and noticeable. I didn't think of it. It is a nice, although difficult case. Congratulations.
Me resulta curioso e interesante. Yo no lo pensé. Es bonito, pero difícil. Felicidades.

- maria isabel lorenzo paz (01/11/2005 21:29:23)

Very good case, and excellent pictures
muy bueno el caso excelente fotografías

- Mirta Garcia Jardon (07/11/2005 16:16:04)

Congratulations for such interesting case and for the very nice presentation and representative pictures. The actual diagnosis never crossed my mind.

Felicidades por su interesante caso, su presentación e imágenes tan representativas. El diagnóstico real del caso jamás me pasó por la mente.