



## Virtual Slide Congress. Case # 10

[- Slides Index](#)

[- Home](#)

**Alexandra Gené<sup>\*</sup>, Terrasa F.<sup>\*</sup>, García M.<sup>\*\*</sup>**

<sup>\*</sup> Hospital Universitario Son Dureta. Palma de Mallorca. ESPAÑA

<sup>\*\*</sup> Hospital Fundación Son Llatzer. Palma de Mallorca ESPAÑA

[- Top](#)

[- Virtual Slide](#)  
[- Case Report](#)  
[- DIAGNOSIS](#)  
[- Pathology](#)  
[- References](#)

### Case Report

74-year-old woman with a previous history of badly controlled asthma that required chronic medication and several hospitalizations.

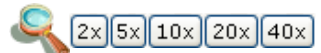
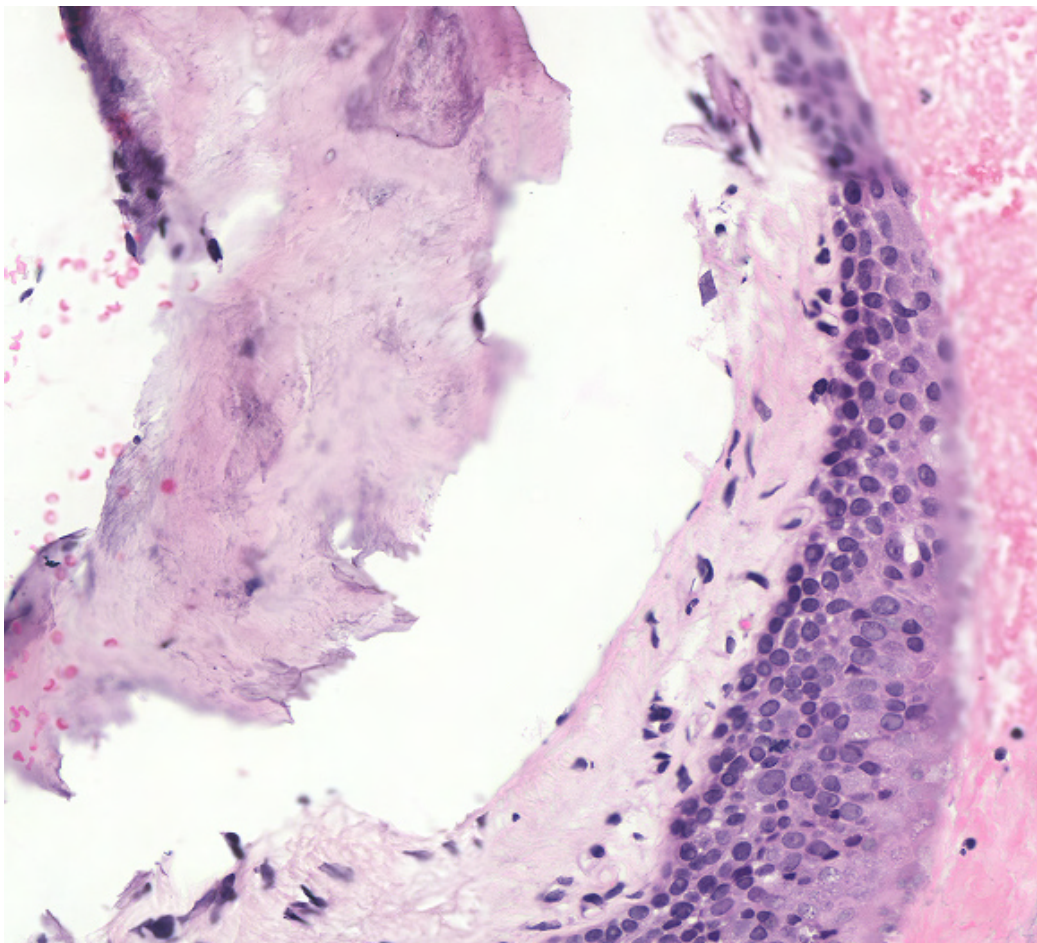
At bronchoscopy, many nodular elevated lesions were seen on all sides of the trachea, giving a "rock garden" appearance.



**WebMicroscope**

This slide's been kindly digitized by [WebMicroscope's team \(Finland\)](#)

Preparación amablemente digitalizada por los responsables de [WebMicroscope \(Finlandia\)](#)



Contrast: 1.00

Brightness: 1.00

Case 10, C10 (x20)

Regions of Interest: [On/Off](#)



[See virtual slide in full window size - Ver caso en Webmicroscope](#)

[- Top](#)

- Virtual Slide  
- Case Report  
- DIAGNOSIS  
- Pathology  
- References

## Diagnosis

- Amyloidosis
- Necrotizing sialometaplasia
- Rheumatoid nodules
- Tracheobronchopathia osteochondroplastica

**FINAL DIAGNOSIS IS BELOW THIS LINE**

- Top

- Virtual Slide  
- Case Report  
- DIAGNOSIS  
- Pathology  
- References

## DIAGNOSIS

TRACHEOBRONCHOPATHIA OSTEOCHONDROPLASTICA

- Top

- Virtual Slide  
- Case Report  
- DIAGNOSIS  
- Pathology  
- References

## Pathology

PATHOLOGIC FINDINGS:  
We received 4 tissue samples that measured 1-2 rnm.

Histologically we could see a respiratory mucosal epithelium without atypia beneath which a tracheal cartilage with ossification is seen.

Tracheobronchopathia osteochondroplastica should be considered in the differential diagnosis as an unusual cause of chronic persistent cough, haemoptysis, persistent atelectasis, and recurrent segmental or lobar infection.

- Top

- Virtual Slide  
- Case Report  
- DIAGNOSIS  
- Pathology  
- References

## References

- 1.- Philip S. Hasleton. Spencer's Pathology of the Lung. 5th Edition.
- 2 - Kart L, Kiraz K, Buyukoglan H, Ozesmi M, Senturk Z, Gulmez 1, Demir R, Oyrnak FS. Tracheobronchopathia osteochondroplastica: two cases and review of literature. Tuberk Toraks. 2004;52(3):268-71.

- Top

- Virtual Slide  
- Case Report  
- DIAGNOSIS  
- Pathology  
- References

## Comments

- **MARIBEL ALTAGRACIA DONASTORG VITTINI** (12/10/2005 22:52:00)

A very interesting case. Congratulations  
*Un caso verdaderamente interesante. Felicidades.*

maribel Donastorg

- **shanthi palanivelu** (13/10/2005 17:53:26)

an uncommon and interesting case-thank you  
shanthi

- **Oscar Marin** (16/10/2005 1:20:48)

Interesting case, unusual I suppose, at least I never see one before today. Congratulations.

- **Juan Pablo Garcia de la Torre** (17/10/2005 8:43:58)

It is really a very interesting case and extremely uncommon. Greetings.  
*Desde luego un caso interesante y extraordinariamente infrecuente. Saludos*

- **Bernardo Weil Lara** (18/10/2005 13:01:37)

It is an outstanding case not only because its low frequency but also because of the clinical data with multiple hospitalisations and, a final diagnostic bronchoscopy.  
*Un caso llamativo no sólo por su rareza histológica sino también por la clínica que conlleva en este caso ingresos múltiples y finalmente broncoscopia diagnóstica.*

**- Mirta García Jardon** (24/10/2005 9:24:16)

A very interesting case. We have one more than 20 years ago (autopsy finding) that we studied with tracheal x-rays in order to publish it, but never did it. Congratulations to the authors.

*Un caso muy interesante. Tuvimos uno hace más de 20 años (hallazgo de autopsia) que preparamos con rayos-X de tráquea y todo para publicar y jam ás lo hicimos. Felicidades a los autores.*

**- Cesáreo Corbacho Cuevas** (24/10/2005 13:44:38)

A very interesting case. Thanks a lot and warmest regards to the authors.

*Un caso muy interesante e infrecuente. Muchas gracias y un saludo muy cordial a los autores.*

**- Ana María Ramos** (25/10/2005 0:38:04)

Unusual and interesting case

*Caso inusitado e interesante.*

**- humberto castañeda pacheco** (25/10/2005 1:20:25)

It is an unusual and interesting case

*Caso infrecuente e interesante*

**- Ma<sup>a</sup> J. ILDE ZAMACOLA ARISTEGUI** (31/10/2005 16:20:21)

Interesting and didactic. Thanks

*Interesante y didáctico. Gracias.*

**- maria isabel lorenzo paz** (01/11/2005 21:13:21)

An excellent case

*excelente el caso*

**- MARÍA ANTONIETA GÓMEZ LAGUNAS** (02/11/2005 0:38:32)

It is so good that you sent the images through Internet, so that we may become familiar with them

*Qué bueno que mandan las imágenes microscópicas por internet, para que nos vayamos acostumbrando*

**- Roberto Barrios** (02/11/2005 15:53:25)

Last week I received one case in consultation. Some time ago I saw another case that was an incidental finding in autopsy. Maybe we could collect a series.

It is a very interesting lesion, with a very difficult management. Greetings.

*La semana pasada tuve recibi en consulta un caso. He visto hace tiempo, otro caso que fue hallazgo "incidental" de autopsia. Quizas podriamos juntar una serie.*

*Se trata de una lesion muy interesante y de dificil manejo. Saludos,  
Roberto Barrios*

**- Victor Leonel Argueta Sandoval** (04/11/2005 4:26:33)

It is a very uncommon case. We rarely see them, only in these activities; but I guess that when we have a difficult case we will remember this one.

*Caso muy raro, casi no se ven, solo en este tipo de actividades; pero seguro que cuando tengamos uno dificil no nos acordemos.*

**- Romualdo Lins** (04/11/2005 4:56:52)

An utmost interesting case. I had never seen one before. Congratulations.

*Um caso extremamente interessante. Nunca havia visto um antes. Parabéns  
Romualdo*

**- HUGO GÓNGORA JARA** (07/11/2005 1:55:04)

Un caso muy interesante, tiene un nombre muy apropiado por las características histológicas. Primera vez que veo uno. Gracias por presentarlo.

**- Javier Muñoz Moreno** (07/11/2005 13:29:33)

Muy bonito el caso. Felicitaciones.

**- LILIA MARGARITA BERNAL MONDRAGÓN** (11/11/2005 3:52:03)

Interesante caso, y cortes representativos, felicidades.

- **MARIA DEL CARMEN VAZQUEZ CASTRO** (18/11/2005 17:43:45)

GRACIAS POR COMPARTIR SUS CASOS CON NOSOTROS. ES LA PRIMERA VEZ QUE VEO ESTA ENTIDAD

---

Web mantenido y actualizado por el [Servicio de informática](#). Modificado: 31/01/2006 2:23:53